



CASE REPORT

Dayel Rosales¹.
Bárbara Castillo².
Jesús Rodríguez².

1. Consulta Privada en Cirugía Maxilofacial, Monterrey, Nuevo León, México.

2. Universidad Autónoma de Nuevo León, Facultad de Odontología, México.

Corresponding author: Bárbara Castillo. Posgrado de Periodoncia e Implantología Oral, Facultad de Odontología, Universidad Autónoma de Nuevo León, Mexico. E. Aguirre Pequeño y Silao, Mitras Centro, Monterrey, N.L. México, CP 64460. Phone: (52-81) 83294000. Extensión: 3192, 3100 EXT 5134. E-mail: barby_castill@hotmail.com .

Receipt: 05/12/2015 **Revised:** 05/20/2015
Acceptance: 06/03/2015 **Online:** 06/03/2015

Gland excision in submandibular sialolithiasis: A case report.

Abstract: It has been shown that about 1% of the population suffers from calculi of the salivary glands; 80% of them occur in the submandibular gland. The aim of this paper is to present a clinical case of a 34-year-old patient, who was diagnosed with submandibular sialolithiasis and treated surgically for the total removal of the lesion and of the salivary gland, removing the swelling and acute pain. The diagnosis and treatment protocol for sialolithiasis of submandibular gland was carried out according to the latest guidelines, resulting in complete remission of the disease, without functional sequelae during the three months of postoperative follow-up.

Keywords: *Sialolithiasis, Salivary gland calculi, Salivary duct calculi, Submandibular gland.*

DOI: 10.17126/joralres.2015.052.

Cite as: Rosales D, Castillo B & Rodríguez J. Gland excision in submandibular sialolithiasis: A case report. *J Oral Res* 2015; 4(4): 271-275.

INTRODUCTION.

Sialoliths or salivary calculi are calcified structures. They are round or oval with a rough texture and usually of yellowish color¹. Calculi consist of minerals like calcium phosphate and hydroxyapatite, in addition to magnesium, potassium and ammonia². Calculi often cause obstruction of the salivary flow, causing pain, inflammation and recurrent infections, a condition known as sialolithiasis³. Sialolithiasis affects 60 million people a year⁴, two men for every woman, and is most prevalent in adults².

The submandibular gland is more susceptible to sialolithiasis (60%)⁵, due to its anatomy and physiology, since saliva is alkaline and has a higher concentration of calcium, phosphate and mucin, which may cause the appearance of foreign bodies in the walls of excretory ducts, contributing to the development of salivary stones⁶.

The etiology of this disease is still unknown²; however Harrison proposed that the inflammatory edema causes partial duct obstruction, resulting in the stagnation of

secretory material rich in calcium that forms a calcified core, which eventually will become a sialolith⁷. Its growth rate has been estimated at 1 millimeter per year⁸.

One of the most common indications for submandibular sialoadenectomy is sialolithiasis⁹. Kukuckova recommended this procedure routinely to prevent future glandular infection¹⁰.

The aim of this paper is to report a case of a 34-year-old female patient diagnosed with intraparenchymal sialolithiasis treated surgically.

CASE REPORT.

Female patient, 34 years old, who attended a private practice in the city of Monterrey, Nuevo Leon, Mexico, after she noticed a swelling in the right submandibular region, that had been increasing in size during the past 18 months. Six months ago she began to feel pain when chewing. Then the woman detected the swelling in submandibular region, which she described as a “ball that grows” during meals. The patient was referred to a maxi-

llofacial surgeon for evaluation.

The patient's medical history showed no pathological clinical data relevant to the current condition, except for tobacco smoking for little over three years, so she was classified as ASA I¹.

The extraoral physical examination showed an increased volume in the right submandibular region. The swelling was firm, mobile on palpation and pressure upon it caused pain (Figure 1). Intraorally, it was possible to visualize the swelling by palpating the lesion extraorally. The patient has had a recent blood count and blood chemistry with normal serum parameters.

Due to the location of the lesion, symptoms and the absence of previous clinical pathological data, it was suspected that the patient was affected by a submandibular sialolith, so a computed tomography (CT) was requested to confirm the presumptive diagnosis.

At the second appointment, the patient brought her CT. It showed a hyperdense area of approximately 1000 Hounsfield Units within the parenchyma of the right submandibular gland, and an increase in the density of adipose tissue surrounding the gland, indicating a chronic inflammatory process (Figure 2). The removal of the calcification, along with the removal of the salivary gland was scheduled. The patient was given preoperative indications before hospitalization.

At the third appointment, the surgical procedure under general anesthesia, with endotracheal intubation, was performed. Using a Risdon submandibular approach, Robbins IB region was exposed and platysma muscle was dissected to observe the submandibular gland. The gland was firm to palpation, and by blunt dissection strong fascia adhesions the gland had with adjacent soft tissue were disinserted. Once mobile to palpation, the gland was turned to locate its salivary duct, which was ligated before performing salivary gland excision (Figure 3). The flap was repositioned and sutured in layers. The patient was instructed not to smoke for four weeks and was prescribed ketorolac 10mg every 6 hours for 5 days, and amoxicillin 500mg every 8 hours for 7 days.

Subsequently, histopathological examination was performed using hematoxylin and eosin. A specimen formed by epithelial cells with cylindrical metaplasia and mucus-secreting cells was observed. Calcified concentric mate-

Figure 1. Extraoral clinical photograph showing a slight increase in volume within the right submandibular region.

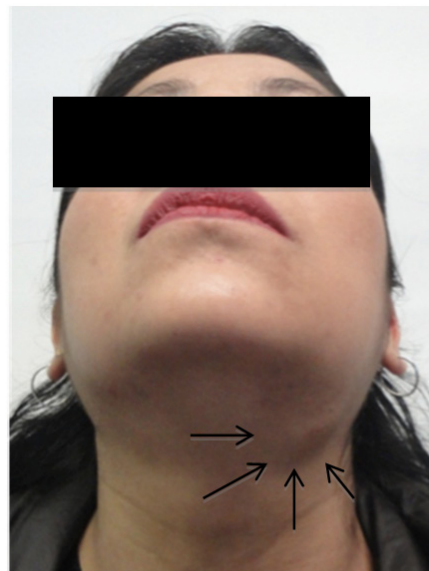

Figure 2. Computed Axial Tomography in bone window of bone tissue. Hyperdense area of 10mm x 10mm x 12mm within the parenchyma of the right submandibular salivary gland is observed.

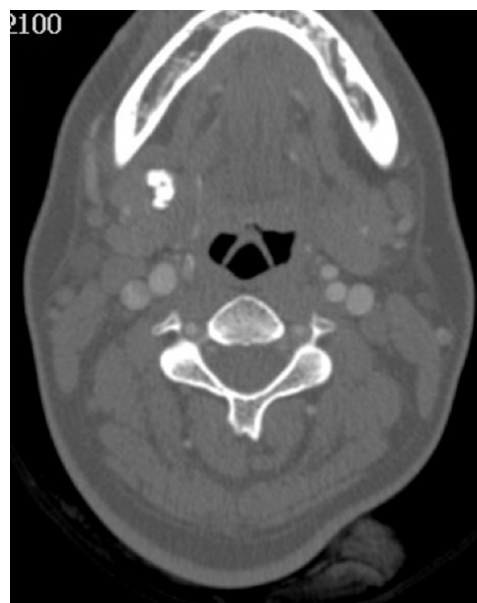


Figure 3. Macroscopy of pathological lesion of the right submandibular gland.

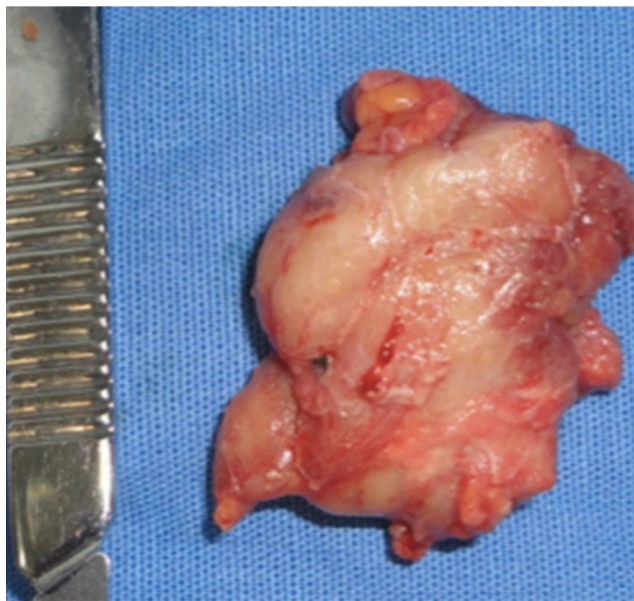
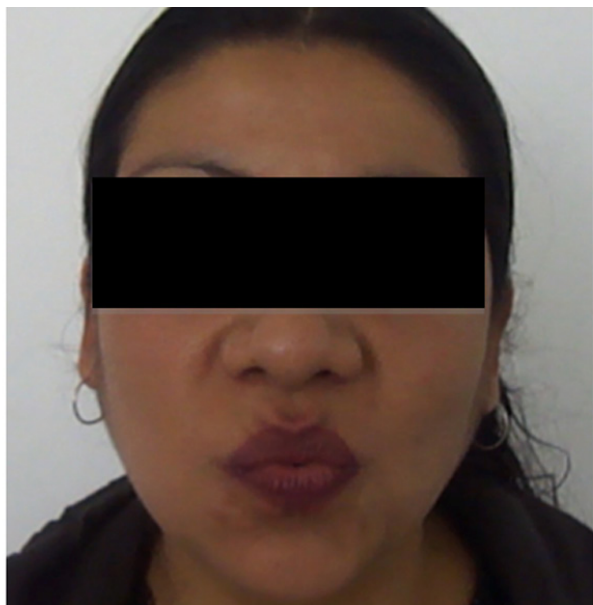

Figure 4. Extraoral clinical photograph taken three months after surgery showing absence of lesion to the marginal mandibular branch of the facial nerve.



rial within a stroma of well-vascularized dense fibrous connective tissue was also observed. Mixed acini with serous predominance were observed. They showed diffuse chronic inflammatory infiltrate, confirming the diagnosis of submandibular sialolithiasis.

At the end of the first postoperative week, the patient reported slight discomfort in the area of surgery; however a significant decrease in volume was observed. After three months, no lesion to the facial nerve was confirmed by asking the patient to make a lip protrusion gesture (Figure 4).

DISCUSSION.

The diagnosis of submandibular sialolithiasis requires an accurate clinical examination by means of X-rays; however, not all sialoliths can be detected radiographically. Many do not show signs and predictable symptoms. CT is currently the preferred diagnostic method because it has demonstrated superior accuracy to detect small stones, in comparison to ultrasound, X-rays¹² and magnetic resonance^{13,14}.

Some authors have reported that submandibular sialolithiasis causes a reduction of the salivary flow¹⁵, while others as Gaetti *et al.* state that salivary flow is increased due to glandular enlargement^{6,16}. In the present case, despite that a sialometry was not performed to check if there was a reduction of the salivary flow, no clinical or symptomatic evidence of changes or alterations occurred in the flow.

In this case it was decided to perform a complete removal of the lesion and of the salivary gland; however, there are other alternatives such as laser technique, which allows the removal of the calculi without glandular excision. The removal of the gland is performed to prevent infection and the development of tumors¹⁷. Yilmaz *et al.* report that when submandibular sialolithiasis becomes symptomatic, producing pain when chewing or inflammation, the calculi and the gland must be removed to relieve these symptoms¹⁸.

Small sialoliths require no invasive techniques and the sialolith may be removed stimulating the salivary gland by localized massage, by mechanical sialogogues such as chewing gum or wax, or chemical sialogogues such as citric acid. However, these techniques are only limited to small sialoliths; large ones should be removed by surgical excision¹.

In conclusion, in this case, the patient diagnosed with submandibular sialolithiasis underwent a surgery to remove the pathological lesion and the submandibular gland. No adverse effects were reported during the three months of postoperative follow-up. It is important to be updated about the different diagnostic methods and treatments to deal with

submandibular sialolithiasis, in order to avoid complications such as recurrent infections and glandular neoplasia.

ACKNOWLEDGEMENTS.

The authors acknowledge Dr. Juan Manuel Solís Soto for his advice during the writing of this paper.

Escisión glandular en sialolitiasis submandibular: Reporte de un Caso

Resumen: Se ha demostrado que alrededor del 1% de la población padece de cálculos de las glándulas salivales, donde el 80% de ellos ocurren en la glándula submaxilar. El objetivo de este artículo es dar a conocer un caso clínico de una paciente de 34 años de edad, quien fue diagnosticada de sialolitiasis submandibular y tratada quirúrgicamente para la remoción total de la lesión, junto con la glándula salival, en donde se obtuvo como

resultado la eliminación del aumento de volumen y el dolor agudo. El protocolo de diagnóstico y tratamiento para la sialolitiasis de la glándula submandibular fue llevado a cabo de acuerdo a los últimos lineamientos, obteniendo la remisión total de la patología, sin presentar secuelas funcionales durante los tres meses de seguimiento postoperatorio.

Palabras clave: *Sialolitiasis, Cálculos del conducto salival, Cálculos de las glándulas salivales, Glándula submandibular.*

REFERENCES.

1. Smita K, Monali G. Sialolithiasis: An Unusually Large Asymptomatic Submandibular Salivary Stone. Case report. SDJ. 2013;1:42-47.
2. Grases F, Santiago C, Simonet BM, Costa-Bauzá A. Sialolithiasis: mechanism of calculi formation and etiologic factors. Clin Chim Acta. 2003;334(1-2):131-6.
3. Selçuk Arslan, Erkan Vuralkan, Bengü Çobanoğlu, Ahmet Arslan, Ahmet Ural. Giant sialolith of submandibular gland: report of a case. J Surg Case Rep. 2015;2015(4):rjv043.
4. Franco A, de Carvalho Mattos MJ, Ferrari F, Dos Reis Neto JM, Carta Gambus LC, Couto Souza PH, Berti-Couto Sde A. Massive Submandibular Sialolith: Complete Radiographic Registration and Biochemical Analysis through X-Ray Diffraction. Case Rep Surg. 2014;2014:659270.
5. Chandra SJ. Submandibular Sialolithiasis Analysis of 4 Case Reports. JIMSA. 2010;3(2):97-8.
6. Jardim ECG, Ponzoni D, de Carvalho PSP, Demétrio MR, Aranega AM. Sialolithiasis of the submandibular gland. J Craniofac Surg. 2011;22(3):1128-31.
7. Harrison JD, Epivatianos A, Bhatia SN. Role of microliths in the etiology of chronic submandibular sialadenitis: A clinicopathological investigation of cases. Histopathology. 1997;31(3):237-51.
8. Marchal F, Dulgerov P. Sialolithiasis management: the state of the art. Arch Otolaryngol Head Neck Surg. 2003;129(9):951-6.
9. Durbec M, Dinkel E, Vigier S, Disant F, Marchal F, Faure F. Thulium-YAG laser sialendoscopy for parotid and submandibular sialolithiasis. Lasers Surg Med. 2012;44(10):783-6.
10. Kukuckova B, Svec M. Surgical management of submandibular gland diseases: ten years of experience. Bratisl Lek Listy. 2011;112(5):264-8.
11. Maloney WJ, Weinberg MA. Implementation of the American Society of Anesthesiologists Physical Status Classification System in Periodontal Practice. J Periodontol. 2008;79(7):1124-6.
12. Kalia V, Kalra G, Kaur S, Kapoor R. CT Scan as an Essential Tool in Diagnosis of Non-radiopaque Sialoliths. J Maxillofac Oral Surg. 2015;14(1):240-4.
13. Noha AM LP, Amr B. Diagnostic accuracy of MR sialography in sialolithiasis and salivary ductal stenosis. Egypt J Radiol Nucl Med. 2013;44(1):45-50.
14. Parkar MI, Vora MM, Bhanushali DH. A Large Sialolith Perforating the Wharton's Duct: Review of Literature and a Case Report. J Maxillofac Oral Surg. 2012;11(4):477-82.
15. Franco A, de Carvalho Mattos MJ, Ferrari F, Dos Reis Neto JM, Carta Gam-

- bus LC, Couto Souza PH, Berti-Couto Sde A. Massive Submandibular Sialolith: Complete Radiographic Registration and Biochemical Analysis through X-Ray Diffraction. *Case Rep Surg.* 2014;2014:659270.
16. Bulut HT. Unusually large sialolith of submandibular gland. *Int J Case Rep Images.* 2014;5(9):625–8.
17. Pastor-Ramos V, Cuervo-Díaz A, Aracil-Kessler L. Sialolithiasis. Proposal for a new minimally invasive procedure: Piezoelectric surgery. *J Clin Exp Dent.* 2014;6(3):e295–8.
18. Yilmaz M, Akil F, Murat H, Aydin F, Özbilen G, Özgun E. Submandibular Gland Excision: 10-Year Outcome. *Otolaryngology.* 2013;3:138.