



## REVIEW

Patricio Robles<sup>1,2</sup>.

Ignacio Roa<sup>1,2</sup>.

1. Departamento de Ciencias Básicas Biomédicas, Facultad de Ciencias de la Salud, Universidad de Talca. Chile.

2. Facultad de Medicina, Universidad de La Frontera. Chile.

Corresponding author: Patricio Robles. Edificio de Ciencias Básicas Biomédicas, Universidad de Talca, Avenida Lircay s/n, Talca. Chile. Phone: 56-71-201682. E-mail: probles@utalca.cl

Receipt: 08/07/2014 Revised: 08/25/2014

Acceptance: 09/09/2014 Online: 09/09/2014

## Keratocystic odontogenic tumor: Clinicopathological aspects and treatment.

**Abstract:** The keratocystic odontogenic tumor is a benign intraosseous neoplasm derived from remnants of the dental lamina and it occurs with high frequency. Regarding histological characteristics, it has a high recurrence rate which is one of the main therapeutic problems. Also, it presents high local aggressiveness, expressed in cortical expansion, delayed eruption and displacement of teeth, blood vessels and nerves. At present, there are various treatments, being ideal the one which presents the lowest risk of recurrence with low morbidity for the patient. In this review, the main histopathological, clinical and therapeutic aspects of this oral pathology are discussed.

**Keywords:** *Keratocystic odontogenic tumor, treatment, decompression, differential diagnose.*

*Cite as: Robles P & Roa I. Keratocystic odontogenic tumor: Clinicopathological aspects and treatment. J Oral Res 2014; 3(4): 249-256.*

### INTRODUCTION.

The Keratocystic Odontogenic Tumor (KCOT) is described as a benign tumor of relatively high prevalence originating from remnants of the dental lamina tissues. In 2005, the World Health Organization (WHO) classified it as an odontogenic tumor due to a number of features which reflect its neoplastic nature<sup>1</sup> since, in some cases, it may undergo malignant transformation (transformation into a squamous cell carcinoma)<sup>2</sup>.

It is usually asymptomatic, becoming evident only as radiographic finding in routine evaluations or check-ups with panoramic radiographs. Since it has a complex operation and high recurrence, knowing its different characteristics is critical to make a correct differential diagnosis and treatment. Such reasoning led this review of literature concerning this important pathology to address topics such as etiopathogenesis, histopathology, diagnosis and treatment.

### EPIDEMIOLOGY AND ETIOPATHOGENESIS.

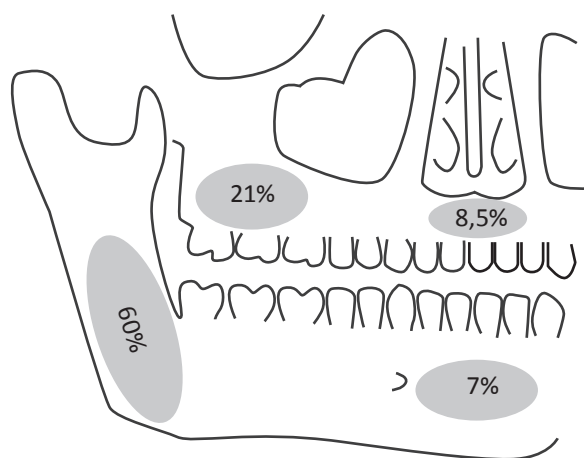
KCOT is a rare injury accounting for 4-12% of odontogenic cysts<sup>3,4</sup>. Though, it has become the most common odontogenic tumor<sup>5</sup> after being reclassified as a tumor. It usually develops in the posterior mandibular area, specifically in the body and mandibular ramus with a probabi-

lity of 60%. While a higher frequency is observed in the molar area in the jaw with 21%<sup>6</sup>, it is uncommon in the anterior maxilla and chin area with 8.5 and 7%, respectively<sup>7</sup> (Fig.1)<sup>8</sup>. In terms of age distribution, it presents its highest prevalence in the second and third decade of life. Despite this, age range is wide and it can appear from the first to the eighth decade of life<sup>3,9</sup>. Regarding gender, it has a higher incidence in males, reaching a ratio of 2:1 compared to females<sup>10</sup>.

It is described as a developmental odontogenic tumor which can originate as an extension of the basal epithelial cells or the dental organ due to degeneration of the stellate reticulum, or odontogenic epithelial remnants in the mandible or maxilla. Three theories have been proposed about the causes for tumor growth: an increase due to basal cell replication, increased osmotic pressure, or release of bone-resorbing factors (enzyme activity in osteolysis)<sup>11-12</sup>.

It is considered that the main cause for the origin of this lesion is a lack of regulation and a mutation in the *PTCH* gene<sup>13</sup>. When changes occur in the *PTCH* gene, there is an associated increased expression of molecules such as bcl-1, p53 and cyclin D. Therefore, cell cycle is altered, with a growth potential and increased proliferation which would trigger KCOT development. This has been explained by the occurrence of

**Figure 1.** Location of KCOTs according to frequency of occurrence (Attaguile *et al.*<sup>8</sup>, with changes.)



phenomena such as allelic losses in the cell genetic material involving KCOT, which leads to a loss of heterozygosity. This phenomenon is also found in basal cell carcinoma and the basal cell nevus syndrome (Gorlin-Goltz)<sup>14,15</sup>. Such feature is prominent due to the association of this syndrome and KCOT (7%), mainly in females<sup>3</sup>. This association could be a common component, since the presence of repeated or multiple KCOT could be an important sign in early diagnosis. In many cases, this early clinical manifestation makes it possible to diagnose the syndrome<sup>3</sup>. Besides presenting multiple KCOT, basal cell carcinomas, spina bifida and cerebral falx calcification are characteristics of this syndrome<sup>3,16</sup>.

### CLINICAL AND RADIOLOGICAL FEATURES.

This kind of injury shows few symptoms and usually appears incidentally on X-rays. Among the symptoms, there is pain, enlargement and swelling due to its capacity to expand cortical bone, making the increase in intraoral volume evident. It may also be colonized and infected by pathogenic microorganisms, producing a subsequent drainage of purulent content. Besides, it can manifest ipsilateral paresthesia due to displacement or nerve compression<sup>17</sup>.

The growth of this lesion has been described as mural, although there may be other types of tumor growth. It develops between the cortical bone, reabsorbing cancellous bone or moving through medullary spaces<sup>18</sup>, rarely drilling

cortical bone but tending to grow in an anteroposterior direction<sup>19</sup>. The size of the lesion can achieve large dimensions and can cause a pathologic fracture<sup>20</sup>.

In the radiological examination, it presents in various ways. The most common feature is a unilocular or multilocular radiolucent area of variable size, 5cm or more; with clear limits distinguishing cortical bone (possibly punctured). Also, it may show scalloped edges and lobed or polycystic appearance. It is common to find dental displacement, including root resorption in teeth neighboring the tumor<sup>1,11,21</sup>.

### HISTOPATHOLOGY.

In the histological examination, a wall of dense (fibrous) connective tissue is observed, and it can be focally separated from the epithelium, with no inflammatory cellular infiltration<sup>3</sup>. It is internally coated by a thin and constant layer of stratified plain parakeratinized epithelium with a thickness of six to ten cellular layers<sup>21</sup>. Basal cells are cuboidal in palisade arrangement with polarized and hyperchromatic nuclei of uniform size. On the surface facing the tumoral lumen, it is possible to find a thin corrugated parakeratin layer with some cell nuclei inside. The absence of epithelial papilla makes the arrangement of the basement membrane rather flat. The capsule is thin and friable. Suprabasal expression of Ki-67 or p53 as growth markers is observed in the epithelium<sup>12</sup>.

Sometimes, it is possible to observe the presence of satellites cysts or tumors within the connective tissue, the epithelium or the wall of the capsule<sup>21</sup>. These have been associated with possible recurrence events related to KCOT and varied rates<sup>22</sup> ranging between 0% and 100%<sup>23</sup> mainly due to two aspects: the type of treatment carried out and the length of time of radiological and clinical follow-up<sup>24</sup>. Another factor that is associated with recurrence is the tumoral membrane, which becomes labile at removal because it is very thin, and friable easily fragmenting and enabling the persistence of tumor remnants into the cavity or the surrounding bone tissue. That makes it clear that the mere removal of the lesion is not always effective to prevent further KCOT occurrences. Therefore, different treatments and their combination

Table 1. Differential diagnoses.

Characteristics	KCOT	Dentigerous cyst	Ameloblastoma	AOT	Ameloblastic fibroma	CGCG
Clinical aspect	Variable size. Slight cortical	Cortical expansion.	Extensive deformities. affection.	Swelling on an unerupted tooth.	Cortical expansion.	Cortical expansion or perforation. Ulceration.
Location	Any area of the mandibular body and ramus.	Related to third molars and maxillary canines.	Mandibular molar area and ascending ramus.	In anterior maxilla.	Mandibular molar area.	Mandibular anterior area.
Sex	Male	No preference.	No preference.	Female.	No preference.	Female.
Age	Second and third decade of life.	Second and third decade of life.	Fourth and fifth decade of life.	Second decade of life.	First to fourth decade of life.	Third decade.
Signs and symptoms	Cortical expansion and paresthesia.	Asymptomatic. Delayed tooth eruption. There might be swelling or pain.	Asymptomatic.	Asymptomatic.	Asymptomatic.	Pain and paresthesia.

have been sought to make the therapeutic approach to these lesions more effective<sup>25</sup>.

Currently, a distinction has been made between true KCOTs and those with a similar histology, but not the same. In the re-classification of this condition, Philipsen<sup>1</sup> excludes the orthokeratotic variable from the category of keratocystic odontogenic tumor, calling it orthokeratotic odontogenic cyst (OOC). Its characteristics are different from KCOT, such as the presence of orthokeratotic keratinization with a granulose layer<sup>10</sup> a lower thickness of the cornea layer, and zero expression of proteins such as tenascin. Furthermore, there is a difference in the amount of synthesis of cytokines 10, 13 and 14, which have higher concentrations in KCOT. A different origin for both lesions has been described too. OOC can derive from epithelial rests of oral and gingival mucosa. All these different histopathologic features of OOC give it a less proliferative potential and a reduced tendency to recurrence<sup>9</sup>. Another big difference, when diagnosing this disease, is its high frequency and similarity with the dentigerous cyst both clinically and radiographically<sup>9</sup>.

## DIFFERENTIAL DIAGNOSIS.

Diagnose of KCOT is mainly done by histopathological analysis and biopsy (Table 1). Among the rele-

vant conditions to perform a differential diagnosis with KCOTs are:

**Dentigerous cyst:** it is an osteolytic lesion which usually leads to misdiagnose due to the similar radiographic features with KCOT, even more when it is solid and unicystic. The difference lies in the association of this lesion with teeth (canine or third molar)<sup>25</sup> which is not found in KCOT. A possible delay in tooth eruption, apart from swelling and pain due to cortical expansion may be present<sup>11,20,26</sup>.

**Lateral periodontal cyst:** it can be confused with a KCOT when the latter is in the mandibular body at premolar level. It is small size with clear limits and unilocular aspect<sup>11,21,27</sup>.

**Ameloblastoma:** it has similar clinical and radiographic features with KCOT when the ameloblastoma is in early stages, since it can then reach large dimensions which produce deformities. In the histopathological exam, proliferative nests surrounded by cells with high polarization, simulating the enamel organ can be observed<sup>21,26</sup>.

**Adenomatoid odontogenic tumor (AOT):** it is associated with impacted teeth and is mainly located in the anterior mandible and maxilla, unlike in KCOT<sup>21,26,27</sup>.

**Ameloblastic fibroma:** like KCOT, it can expand the cortical bone. In the radiological examination, it is presented as a mixed lesion with radiolucent and radiopaque images contrary to the KCOT which is a purely radiolucent lesion. Histologically, it has a fibrous capsule, different from KCOT<sup>11,21,27</sup>.

**Central giant cell granuloma (CGCG):** it may mislead to confusion since it occurs in similar age groups and is clinically similar to KCOT. However, it has different evolution times so there may be expansion or perforation of cortical and ulceration. Histology is different as well; since there is a proliferation of fibroblasts in a collagen lattice, besides multinucleated giant cells<sup>11,21</sup>.

## TREATMENT.

The treatments proposed for the resolution of this condition are varied and have changed over time. In the beginning and in the absence of less invasive treatment options, total resection of the lesion was postulated as the treatment of choice, given that the maximum amount of diseased tissue was removed for clinical success. This was associated with high morbidity for the patient, loss of bone structure, and even nerve damage or weakening of bone bases. For this reason, other alternatives were sought hoping to find an option which would respect the actual anatomical structures, leading to the least damage and the maximum benefit. This is only possible considering specific injury factors, such as its extent and location, involving degree of neighboring structures, nerves, blood vessels, teeth and soft tissues<sup>28</sup>. The state and the amount of remaining bone is also an important factor to consider<sup>25</sup>.

Considering the need to obtain a low morbidity for the patient, all treatments have been classified into two main groups<sup>29</sup>, (Table 2).

Enucleation is a non invasive treatment seeking to eliminate all tumor tissue including its membrane<sup>17</sup>. Enucleation has a high recurrence rate when used as the only technique so it has been combined with other elements. Carnoy's solution has the effect of cauterizing the tumor cells, and the possible adverse effect of tem-

**Table 2.** Classification of treatments for the keratocystic odontogenic tumor according to Blanas *et al.*<sup>29</sup>; 2000.

CONSERVATIVE TREATMENTS	AGGRESSIVE TREATMENTS
Enucleation.	Enucleation and peripheral osteotomy.
Enucleation and curettage.	Enucleation and Carnoy's solution application.
Decompression and marsupialization.	Cryotherapy.
Enucleation and decompression	Resection without continuity defect. Resection with continuity defect. Disarticulation section.

porary nerve damage with paresthesia. This has proven satisfactory, although cases of recurrence have been described in KCOTs treated this method<sup>30</sup>. In replacement of Carnoy's solution, electrocautery of the area has been used, obtaining similar results<sup>29,31</sup>. Enucleation using liquid nitrogen (cryotherapy) has been tried because of the capacity of devitalizing the bone in the area of the lesion, leaving a thin layer of inorganic fabric intact. It produces cell death through the formation of ice crystals in and around the cell, generating disturbances in the osmosis and electrolytic balance<sup>25</sup>.

Other methods used are curettage, peripheral osteotomy and marsupialization<sup>23</sup>.

It is true that recurrence of KCOT is one of the greatest risks and the only treatment which has been shown to minimize it is the total bloc resection. However, undesirable consequences and significant morbidity for the person are generated, although bone block grafts to treat bone defects produced by the total resection have been tried<sup>29,31</sup>.

Since the treatment with the lowest recurrence rate generates significant morbidity for the patient, decompression of KCOTs has been proposed as a treatment of choice because it is capable of producing lower morbidity for the subject and better results. Marsupialization, as described by Partsch, releases intraluminal pressure generating a pocket to communicate the entire tumor with the external environment<sup>32</sup>.

Some authors describe techniques for decompression and marsupialization as similar, without distinguishing them as to the principles and method which constitute each one. Decompression is the release of the internal pressure of the lesion which generates continuity between the external and internal environment and the use of a device is necessary. This can be attached to the edges of the wound with sutures, thus, ensuring this communication is kept open at all times, preventing spontaneous closure and allowing sanitation of the inner zone of the lesion to prevent bacterial growth or accumulation of food. Furthermore, marsupialization comprises releasing pressure inside the lesion but one of the main principles is to generate a marsupial internal pocket breaking all septa either bone or mucus, and making the suture of the wound with healthy oral mucosa necessary to maintain communication<sup>23</sup>.

These techniques aim to generate morphological changes in the capsule through constant trauma due to food impaction and constant lavage of the cavity with sterile saline solution or 0.12% chlorhexidine, which generates swelling of the capsule, making it thicker and more rigid to favor complete removal without leaving traces or residues. Along with this, it seeks to cause minor trauma regarding the size and tissues involved, trying to protect the integrity of important structures. Restoring functionality in the shortest healing time possible is another purpose of this technique<sup>33,34</sup>.

Decompression has been questioned by some authors, since they suggest that not all the affected tissue can be removed, and the presence of some satellites cysts or remnants of its membrane can be left in the place<sup>34</sup>, favoring recurrence of injury for reactivation and proliferation of these remains. On the other hand, it has been suggested that recurrence rates of KCOT undergoing decompression treatment are similar to cysts undergoing further treatment, between 1 and 8.7%<sup>3</sup>.

Regarding the removal of the device and posterior planning of the remnant tumor enucleation, the evidence is controversial, since ideally it should be evaluated case by case and the evolution of the current treatment should be obser-

ved, keeping in mind the original size after decompression of the lesion. The obvious clinical and radiographic changes will not be observed in less than 6 months and the treatment could even be extended to one year<sup>34</sup>.

Morphological changes at macroscopic and microscopic level may be observed in tumors treated by decompression. A macroscopic increase of the tumor membrane occurs due to swelling produced by the constant trauma generated when exposing the tissue to rub against the elements in the oral environment, such as food. Then, a thicker and less friable tumor capsule is obtained and it allows removal with higher success rates and lower risk of residual tumor remaining in cavity<sup>35</sup>.

Furthermore, the changes occurring at microscopic level are increased inflammatory infiltration in the connective tissue, and epithelial metaplasia due to constant injury is observed in the epithelium. The epithelium increases in thickness from the former 6 to 10 cell layers, causing epithelial hyperplasia. The epithelium changes from a thin parakeratinized epithelium to a hyperplastic nonkeratinized squamous epithelium. Bone adherence decreases, thus favoring its subsequent release, and stopping to secrete bone resorption factors, osteoclast activity, and tumor growth. In turn, bone formation begins together with a decrease in tumor size, being able to completely diminish thus making surgery unnecessary. Furthermore, it has been reported that expression of tumor growth factors, such as Ki-67, PCNA or p53, decrease when undergoing decompressing treatment<sup>25,33,35</sup>.

The possibility of applying this decompression treatment to cystic and tumor pathology of the jaws has brought a new option for the management of lesions in patients of different ages. In pediatric patients, who are growing and their bone bases are not fully established, a radical treatment such as resection brings permanent consequences for the patient's life and development. Therefore, decompression is an option with low morbidity, low recurrence rates and in which there is an observed reduced lesion size and it may even disappear. A major factor in the success of this technique is properly trac-



king the patient through regular check-ups to clinically assess the evolution and remission of the lesion. For this, it is necessary to have family support and commitment to treatment<sup>29</sup>.

## DISCUSSION.

KCOT is a benign entity arising from remnants of the dental lamina with a relatively high prevalence. It has a potential aggressive behavior and a high recurrence rate<sup>2,3</sup>. Multiple authors have reported their invasive potential, due to its capacity to slowly grow in the anteroposterior marrow spaces, and can be transformed into a large lesion without causing notorious expansion<sup>2,3</sup>.

A noteworthy aspect is its relationship with the basal cell nevus syndrome, which is associated with 7% appearing mostly in the females<sup>3</sup>. Apart from associating with multiple KCOTs, it can also present basal cell carcinomas, spina bifida and cerebral falx calcification.

Due to the absence of symptoms, it is evident as a radiographic finding during tests or check-ups with panoramic radiographs. In imaging studies, they are generally seen as a unilocular or multilocular radiolucent area with well-demarcated edges<sup>4,7</sup>. Besides radiography, computed tomography and nuclear magnetic resonance with contrast are good diagnostic methods. They can be used to assess cortical bone perforation or a possible evolution in soft tissues<sup>3</sup>.

New treatment strategies are still being proposed, although they are sometimes controversial. The challenge still lies in reducing the risk of recurrence and morbidity of an extensive resection<sup>18</sup>. Recurrence causes are essentially due to incomplete removal of the cystic membrane and growth from small cysts satellites or epithelial nests left after enucleation<sup>19</sup>. Multiple treatment modalities have been employed in both conservative and radical management of KCOTs. Among conservative treatments, it can be found: marsupialization or decompression, simple enucleation, enucleation with curettage peripheral (mechanical or chemical), decompression followed by enucleation. Radical surgical treatments are more aggressive and may comprise marginal or block resection, and hemimaxillectomy or hemimandibu-

lectomy<sup>24</sup> considering decreased quality of life as a possible complication. To prevent recurrence, the use of adjuvants or chemical curettage like cryotherapy with liquid nitrogen or Carnoy solution has been recommended in order to eliminate possible satellite cysts in the bone limits<sup>3</sup>. The most widely used is the Carnoy solution, which penetrates between the trabecular bones, devitalizing and attaching tumoral cells<sup>24</sup>.

According to multiple studies reported in literature, this disease presents variable recurrence rates<sup>23</sup> which are mostly seen in the first five years after surgery<sup>19</sup>. Higher rates are reported with the single treatment of enucleation (17-56%). If it is assisted with Carnoy solution or decompression prior to enucleation, it decreases from 1 to 8.7%<sup>3,24,30</sup>. Finally, resection is reported as a treatment without recurrences, although it is controversial given the benign nature of the disease and the numerous associated complications such as facial deformation, tooth loss, infection of the transplanted graft and sensory alterations due to damaged nervous elements<sup>3,7,24</sup>.

## CONCLUSION.

Keratocystic odontogenic tumor is now the subject of multiple studies, which put their main emphasis on its pathological aspects, clinical presentation, course and treatment. Since this condition does not present any symptoms, early diagnosis is critical in order to indicate the optimal treatment to slow down evolution and prevent complications. KCOT is presented as a pathology that can be mutilating, altering the person's life. Although it does not have a malign nature, it generates significant secondary changes and it is necessary to seek appropriate treatment from every possible aspect.

Knowing the various aspects of KCOT and using appropriate diagnostic means (histopathology and imaging) allow a correct diagnosis and treatment of injuries. Therefore, it is important that the clinical dentist has the necessary diagnostic tools to provide a favorable prognosis for the patient through a correct treatment planning.

This review provides essential information for understanding KCOT, aiming to provide a simple summary of the current knowledge about this disease in order to contribute to future studies in this area.

## Tumor odontogénico queratoquístico: Aspectos clínico-patológicos y tratamiento.

**Resumen:** El tumor odontogénico queratoquístico es una neoplasia intraósea benigna que deriva de restos de la lámina dental, y que se presenta con alta frecuencia. Sus características histológicas le confieren una elevada tasa de recidiva, siendo este uno de sus principales problemas terapéuticos. Presenta además una considerable agresividad local, la cual se expresa con la expansión de corticales

óseas, retardo en la erupción y desplazamiento de dientes, vasos sanguíneos y nervios. En la actualidad existen diversos tratamientos, siendo el ideal aquel que presente el menor riesgo de recidiva con una baja morbilidad para el paciente. En la presente revisión se discuten los principales aspectos histopatológicos, clínicos y terapéuticos de esta patología oral.

**Palabras clave:** *Tumor odontogénico queratoquístico, tratamiento, descompresión, diagnóstico diferencial.*

## REFERENCES.

1. Philipsen H. World Health Organization Classification of Tumours. Pathology and Genetics of Head and Neck Tumours. 2005 International Agency for Research on Cancer (IARC), Chapter 6, 306-7.
2. Cadena AJL, Muñoz LG, Tapia PDC, Flores TA, Orozco JME. Queratoquiste odontogénico. Revisión de 20 años en la Unidad Médica de Alta Especialidad, Hospital de Especialidades CMN «La Raza» IMSS 1980- 2000. Rev Mex Cir Bucal Maxilofac 2010; 6(1):4-13.
3. Grasmuck EA, Nelson BL. Keratocystic odontogenic tumor. Head Neck Pathol 2010; 4(1): 94-6.
4. Shimamoto H, Kishino M, Okura M, Chindasombatjaroen J, Kakimoto N, Murakami S, Furukawa S. Radiographic features of a patient with both cemento-ossifying fibroma and keratocystic odontogenic tumor in the mandible: a case report and review of literature. Oral Surg Oral Med Oral Pathol Oral Radiol Endod 2011; 112(6): 798-802.
5. Servato JP, de Souza PE, Horta MC, Ribeiro DC, de Aguiar MC, de Faria PR, Cardoso SV, Loyola AM. Odontogenic tumours in children and adolescents: a collaborative study of 431 cases. Int J Oral Maxillofac Surg 2012; 41(6): 768-73.
6. Anavi Y, Gal G, Miron H, Calderon S, Allon D. Decompression of odontogenic cystic lesions: clinical long term study of 73 cases. Oral Surg Oral Med Oral Patol Oral Radiol Endod 2011; 112(2): 164-9.
7. Boffano P, Ruga E, Gallezio C. Keratocystic odontogenic tumor (odontogenic keratocyst): preliminary retrospective review of epidemiologic, clinical, and radiologic features of 261 lesions from University of Turin. J Oral Maxillofac Surg 2010; 68(12): 2994-9.
8. Attaguile A, Bianchi M, Benitez J, Zubillaga Y, Giannunzio G Tumor odontogénico queratoquístico. Presentación de un caso clínico y revisión de la bibliografía. Rev Fac de Odon UBA 2012; 27(62): 6-10.
9. Leite TC, Meirelles JV, Janini MER. Odontogenic keratocystic tumor: A clinical and histopathologic retrospective study based on the new WHO classification. Int J Odontostomat 2011; 5(3): 227-34.
10. Dong Q, Pan S, Sun L, Li T. Orthokeratinized Odontogenic Cyst. A Clinicopathologic Study of 61 Cases. Arch Pathol Lab Med 2010; 134: 271-5.
11. Sapp P. Patología Oral y Maxilofacial Contemporánea. 2 ed. Madrid: Elsevier Mosby; 2005.
12. Regezi JA, Sciubba JJ, Jordan RCK. Oral Pathology: Clinical Pathologic Correlations. 6 ed. Chicago: Elsevier Saunders; 2012.
13. Vered M, Peleg O, Taicher S, Buchner A. The immune profile of odontogenic keratocyst (keratocystic odontogenic tumor) that includes expression of PTCH, SMO, GLI-1 and bcl-2 is similar to ameloblastoma but different from odontogenic cysts. J Oral Pathol Med 2009; 38: 597-604.
14. Mendes RA, Carvalho JF, van der Waal I. Biological pathways involved in the aggressive behavior of the keratocystic odontogenic tumor and possible implications for molecular oriented treatment - an overview. Oral Oncol 2010; 46(1): 19-24.
15. Li TJ. The odontogenic keratocyst: a cyst, or a cystic neoplasm? J Dent Res 2011; 90(2): 133-42.
16. Kimonis VE, Singh KE, Zhong R, Pastakia B, DiGiovanna JJ, Bale, SJ. Clinical and radiological features in Young individuals with nevroid basal cell carcinoma syndrome. Gen Med 2013; 15(1): 79-83.
17. Titinchi F, Nortje CJ. Keratocystic odontogenic tumor: a recurrence analysis of clinical and radiographic parameters. Oral Surg Oral Med Oral Pathol Oral Radiol. 2012; 114: 136-42.
18. Ayoub MS, Baghdadi HM, El-Kholy M. Immunohistochemical detection of laminin-1 and Ki-67 in radicular cysts

- and keratocystic odontogenic tumors. BMC Clin Pathol 2011; 11: 4.
19. Tonietto L, Borges HO, Martins CA, Silva DN, Sant'Ana Filho M. Enucleation and liquid nitrogen cryotherapy in the treatment of keratocystic odontogenic tumors: a case series. J Oral Maxillofac Surg 2011; 69(6): e112-7.
20. Peñón Vivas PA, Sarracent Pérez H, Moreira Rodríguez, P. Reemplazo articular temporomandibular debido a queratociste odontogénico. Rev Cubana Estomatol 2013; 49(1): 109-18.
21. Neville BW, Damm DD, Allen CM., Bouquot JE. Patología Oral e Maxilofacial. 3 ed. Chicago: Saunders Company; 2009.
22. Kuroyanagi N, Sakuma H, Miyabe S, Machida J, Kaetsu A, Yokoi M, Maeda H, Warnakulasuriya S, Nagao T, Shimozato K. Prognostic factors for keratocystic odontogenic tumor (odontogenic keratocyst): analysis of clinico-pathologic and immunohistochemical findings in cysts treated by enucleation J Oral Pathol Med 2009; 38: 386-92.
23. Güler N, Sençift K, Demirkol Ö. Conservative management of keratocystic odontogenic tumors of jaws. Sci World J. 2012; 2012:680397.
24. Kaczmarzyk T, Mojsa I, Stypulkowska J. A systematic review of the recurrence rate for keratocystic odontogenic tumour in relation to treatment modalities. Int J Oral Maxillofac Surg 2012; 41(6): 756-67.
25. Abdullah, WA. Surgical treatment of keratocystic odontogenic tumour: A review article. Saudi Dent J 2011; 23(2): 61-5.
26. Shafer WG, Hine MK, Levy BM. Tratado de Patología bucal. 4 ed. Mexico, D.F: Nueva Editorial Interamericana; 2001.
27. Regezi J, Sciubba JJ. Patología Bucal. México. Mexico, D.F: Interamericana Mc Graw Hill; 1991.
28. Kolokythas A, Fernandes R, Pazoki A, Ord R. Odontogenic Keratocyst: To Decompress, or Not to Decompress? A Comparative Study of Decompression and Enucleation Versus Resection/Peripheral Osteotomy. J Oral Maxillofac Surg 2007; 65: 640-4.
29. Blanas N, Freund B, Schwartz M, Furst I. Systematic review of treatment and prognosis of the odontogénico keratocyst. Oral Surg Oral Med Oral Pathol Oral Radiol Endod 2000; 90: 553-8.
30. Mendes RA, Carvalho JF, van der Waal I. Characterization and management of the keratocystic odontogenic tumor in relation to its histopathological and biological features. Oral Oncol 2010; 46: 219-25.
31. Johnson NR, Batstone MD, Savage NW. Management and recurrence of keratocystic odontogenic tumor: a systematic review. Oral Surg Oral Med Oral Pathol Oral Radiol. 2012; 116(4): e271-6.
32. Nakamura N, Mitsuyasu T, Mitsuyasu Y, Taketomi T, Higuchi Y, Ohishi M. Marsupialization for odontogenic keratocyst: Long term follow-up analysis of the effects and changes in growth characteristics. Oral Surg Oral Med Pathol Oral Radiol Endod 2002; 94: 543-53.
33. Pogrel M. Treatment of Keratocysts: The Case for Decompression and Marsupialization. J Oral Maxillofac Surg 2005; 63: 1667-73.
34. Zhao Y, Liu B, Han Q, Wang S, Wang Y. Changes in Bone Density an Cyst Volume After Marsupialization of Mandibular Odontogenic Keratocyst (Keratocystic Odontogenic Tumours). J Oral Maxillofac Surg 2011; 69: 1361-66.
35. Giuliani M, Battista G, Lajolo C, Bisceglia M, Herb K. Conservative management of a large Odontogenic Keratocyst: report a case and review of the literature. J Oral Maxillofac Surg 2006; 64: 308-16.