

## ***In situ* endoscopic analysis of bone microstructure and vascularization in the post-explantation cavities from patients diagnosed with advanced peri-implantitis lesions: A preliminary report.**

Análisis endoscópico *in situ* de la microestructura ósea y la vascularización en las cavidades posteriores a la explantación de pacientes diagnosticados con lesiones avanzadas de periimplantitis: Un informe preliminar.

Víctor Beltrán.<sup>1</sup>

Pablo Acuña-Mardones.<sup>1</sup>

Vanessa Sousa.<sup>2</sup>

### **Affiliations:**

<sup>1</sup>Universidad de La Frontera, Dental School, Clinical Investigation and Dental Innovation Center (CIDIC) and Center for Translational Medicine (CEMT-BIOREN), Temuco, Chile

<sup>2</sup>Centre for Oral Clinical Research, Institute of Dentistry, Barts & The London School of Medicine & Dentistry, QMUL, London, UK.

**Corresponding author:** Víctor Beltrán. Depto Integral del Adulto, Facultad de Odontología, Universidad de La Frontera, Manuel Montt # 112, Temuco, Chile. **Phone:** (56-45) 2325775. **E-mail:** victor.beltran@ufrontera.cl

### **Cite as:**

Beltrán V, Acuña-Mardones P & Soussa V. *In situ* endoscopic analysis of bone microstructure and vascularization in the post-explantation cavities from patients diagnosed with advanced peri-implantitis lesions: A preliminary report.

J Oral Res 2020; S1(1):7-9

**Doi:**10.17126/joralres 2020.025

### **INTRODUCTION**

There is limited information available regarding the morphology of peri-implant bone tissue in implants affected by advanced peri-implantitis in humans. In this context, short distance support immersion endoscopy (SD-SIE) has the potential of performing *in vivo* histological bone evaluation in the explantation bone sites, in which continuous irrigation is used for rinsing areas of interest to obtain clear and precise images. Within the same framework, endoscopic inspection of the post-explantation bone cavities provides a unique opportunity for *in vivo* observation of alveolar bone structures and microvascular hemodynamics.

Thus, during the endoscopically assisted explantation (EAE), it is possible to perform precise intraoperative examination of the blood vessels area, unmineralized bone space and occasional foreign bodies on the internal bone surface.

The objective was to perform a hemodynamic *in vivo* assessment of the post-explantation bone site by SD-SIE. Therefore, it is possible to quantify the bone microstructure and vascularization in the post-explantation cavity through intra-operative high magnification clinical imaging.

**Patient selection:** A descriptive study was performed. A total of 20 video-endoscopies were obtained from six explantations performed with trefine due to advanced peri-implant lesions, two correspond to mandible implants and four to maxillary (one male, four females, aged 33 to 52 years old, function time of implants from 12 to 36 months).

The EAEs were performed considering diagnosis of peri-implantitis based on the classification proposed by the 2017 World Workshop of Classification of Peri-implant Disease<sup>1</sup> and an advanced bone loss (>50%) around the implant evaluated by cone beam CT with an important aesthetic compromise, not presenting mobility. Participants signed informed consent at their visit to the implant clinic of the Dental School, Universidad de La Frontera, Temuco, and the Periodontal Clinic of the Dental School of

Universidad de Concepción, Chile. The study was conducted in line with the principles outlined in the Declaration of Helsinki (2018) on experimentation involving human participants.

Ethical approval to carry out the study was granted by the Universidad de la Frontera Ethics Committee, Report N°024\_2018. Support immersion endoscopy (SD-SIE): A fully mounted endoscope consists of an endoscopic video camera with a magnification regulator that allows for macro and micro zoom. An endoscope of 2.7mm of diameter is inserted into a sheath that provides both support and an irrigation system (Karl Storz, Tuttlingen, Germany).

During the EAE, the irrigation solution is injected using a syringe that is connected by a cannula to the endoscope sheath. In order to perform an endoscopic navigation within the bone explantation cavity, the endoscope support must be at a short distance from the bone surface, practically in contact with it, as when small implant bone cavities are evaluated. A suction system is also needed to control fouling due to bleeding.

#### Microscopic bone imaging analysis (MBI)

The activity of microcapillaries can be registered when the irrigation system is not activated. Conversely, it is possible to appreciate the occlusion of the small blood vessels and unmineralized space when the irrigation system is activated.

Therefore, this method consists in an intraoperative microscopic bone visualization in real time.<sup>2,3</sup> The

processing and analysis of selected frames was performed using the ImageJ software. For that purpose, the brightness and contrast parameters were adjusted, to later quantify the relative area of the elements of interest such as: Blood vessels area (VA), relative unmineralized bone area (UMBA), and foreign bodies area (FBA) in case they are detected (Figure 1).

#### Classification of peri-implant bone defects

The classification of peri-implant defects evaluated by Cone Beam CT was used as described before.<sup>4</sup>

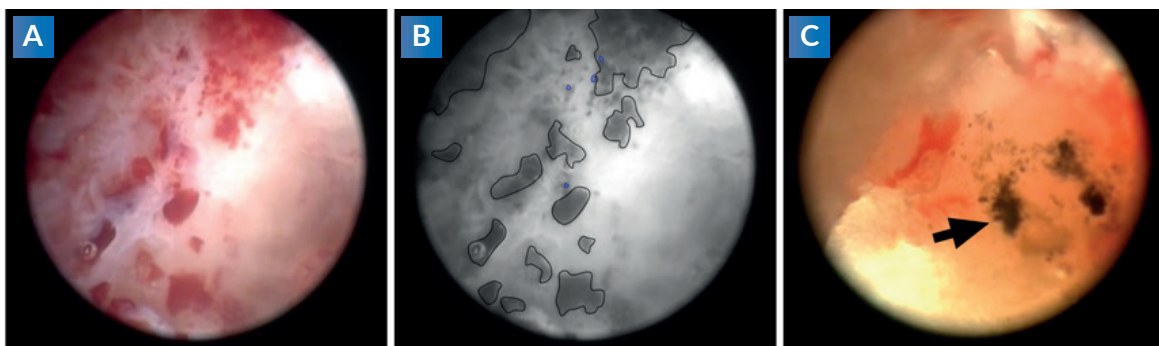
This classification consists of three classes according to containment: Class I or entirely contained (including all bowl-shaped defects), Class II or containment partially lost, and Class III or including horizontal defects without containment.

#### RESULTS

Different distribution of UMBA and VA were identified during EAE. In the peri-implant bone defect Class I, the presence of UMBA was between 37.9% to 38.9% and VA between 0.2% to 4.2%; for peri-implant defects Class II, UMBA was registered between 15.1% to 33.1% and VA between 0.1% to 0.2 %.

Finally, in the peri-implant bone defect Class III, we quantified UMBA between 21.3% to 33% and VA from 0.0% to 0.3%. FBA was detected during EAE in the three types of peri implant bone defect in percentages less to 0.5% of the total area of interest, Class I: 0.25%; Class II: 0.15%; and Class III: 0.3%, on average.

Figure 1. Microscopic bone imaging analysis of bone post-explantation cavities.



A: Original frame obtained from video-endoscopy when the irrigation system is activated.  
B: Area of interest was processed as a 8-bits grayscale image by ImageJ software (VA: blue line; UMBA: black line).  
C: Foreign bodies on the internal bone surface.

## DISCUSSION

The endoscopic findings in post-explantation bone sites showed a variable distribution of VA and UMBA. Additionally, FBA was detected in some bone explanation cavities, which might be compatible with detached titanium particles or trefine scaling.

Regarding other results by our research group using the same methodology in  $\beta$ -TCP grafted and ungrafted post-extraction sites before implant placement, similar results were found for the VA ranges.<sup>3</sup> However, the endoscopic bone examination in advanced peri-implantitis lesions showed lower proportions of UMBA in relation to native and previously regenerated bone sites. It was also interesting to find almost undetectable proportions of VA in Class II and III peri-implant bone defects, in comparison to a pericrateral bone defect (Class I), which presents values similar to a native bone

site as reported by Beltrán *et al.*<sup>3</sup> This could be related to a diminished vascular supply in peri-implant bone defects with partial or total loss of one or all its bone walls around the implant.

These observations might play a role in the success of regenerative therapies for peri-implant bone defects. However, due to the limitations of this preliminary report, further studies with larger cohorts of patients are necessary to achieve more robust results.

---

**Acknowledgements:** This study was funded by Proyecto REDI170658, CONICYT-Chile. The authors would like to thank Ms. Angela Mardones from the Finance and Human Resources Unit of the Faculty of Dentistry (UFRO), for her kind assistance in handling all administrative details in relation to this project.

## REFERENCES.

1. Berglundh T, Armitage G, Araujo MG, Avila-Ortiz G, Blanco J, Camargo PM, Chen S, Cochran D, Derks J, Figuero E, Hämmerle CHF, Heitz-Mayfield LJA, Huynh-Ba G, Iacono V, Koo KT, Lambert F, McCauley L, Quirynen M, Renvert S, Salvi GE, Schwarz F, Tarnow D, Tomasi C, Wang HL, Zitzmann N. Peri-implant diseases and conditions: Consensus report of workgroup 4 of the 2017 World Workshop on the Classification of Periodontal and Peri-Implant Diseases and Conditions. *J Periodontol.* 2018;89 Suppl 1:S313-S318.
2. Engelke W, Lazzarini M, Stühmer W, Beltrán V. Support Immersion Endoscopy in Post-Extraction Alveolar Bone Chambers: A New Window for Microscopic Bone Imaging In Vivo. *PLoS One.* 2015;10(12):e0145767.
3. Beltrán V, Lazzarini M, Figueroa R, Sousa V, Engelke W. In Situ Endoscopic Analysis of Vascular Supply and Regenerated Alveolar Bone in  $\beta$ -TCP Grafted and Ungrafted Postextraction Sites before Implant Placement: A Prospective Case Control Study. *Biomed Res Int.* 2019;2019:2797210.
4. Bender P, Salvi GE, Buser D, Sculean A, Bornstein MM. Correlation of Three-Dimensional Radiologic Data with Subsequent Treatment Approach in Patients with Peri-implantitis: A Retrospective Analysis. *Int J Periodontics Restorative Dent.* 2017;37(4):481-489.