

Expression of CD44 in previously grafted alveolar bone.

Expresión del marcador óseo CD44 en hueso alveolar previamente injertado.

Ricardo Ernesto Dueñas-Villamil.¹
Leticia Belén Bernard-Gutiérrez.²
Diana Susely Hernández-Chavarría.³
Mercedes Olaya-Contreras.⁴
Nelly Stella Roa-Molina.¹
Adriana Rodríguez-Ciodaro.¹

Affiliations:

¹Centro de Investigaciones Odontológicas, Facultad de Odontología, Pontificia Universidad Javeriana. Bogotá, Colombia.

²Práctica privada. Guadalajara, México.

³Facultad de Odontología, Universidad Francisco Marroquín, Guatemala.

⁴Facultad de Medicina, Pontificia Universidad Javeriana. Colombia.

Receipt : xx/xx/2020 Revised: xx/xx/2020
Acceptance: xx/xx/2020

Corresponding author: Ricardo Ernesto Dueñas-Villamil. Centro de Investigaciones Odontológicas, Facultad de Odontología, Pontificia Universidad Javeriana. Carrera 7 No. 40-62, edificio 26 piso 4, Bogotá, Colombia. **Phone:** (57-1) 3208320. **E-mail:** reduenas@javeriana.edu.co

Abstract: Objective: To determine the expressions of the bone surface marker CD44 in samples of alveolar bone previously regenerated with allograft, xenograft, and mixed, using the technique of guided bone regeneration. **Material and Methods:** This exploratory study was approved by the institutional research and ethics committee. By means of intentional sampling and after obtaining informed consent for tissue donation, 20 samples of alveolar bone previously regenerated with guided bone regeneration therapy with particulate bone graft and membrane were taken during implant placement. The samples were stained with hematoxylin-eosin for histological analysis, and by immunohistochemistry for the detection of CD44. **Results:** Sections with hematoxylin-eosin showed bone tissue with the presence of osteoid matrix and mature bone matrix of usual appearance. Of the CD44+ samples, 80% were allograft and 20% xenograft. The samples with allograft-xenograft were negative. There were no differences in the intensity of CD44 expression between the positive samples. The marker was expressed in osteocytes, stromal cells, mononuclear infiltrate, and some histiocytes. Eighty percent of the CD44+ samples and 100% of the samples in which 60 or more cells were labelled corresponded to allografts ($p=0.000$). A total of 67% of the samples from the anterior sector, and 40% from the posterior sector were CD44+ ($p=0.689$). **Conclusion:** This study shows for the first time that guided bone regeneration using allografts is more efficient for the generation of mature bone determined by the expression of CD44, compared to the use of xenografts and mixed allograft-xenograft, regardless of the regenerated anatomical area.

Keywords: Bone regeneration; CD44 protein, human; osteocytes; dental implants; allografts; heterografts.

Cite as: Dueñas-Villamil RE, Bernard-Gutiérrez LB, Hernández-Chavarría DS, Olaya-Contreras M, Roa-Molina NS & Rodríguez-Ciodaro A.

Expression of CD44 in previously grafted alveolar bone.

J Oral Res 2020; 9(6):449-456.

Doi:10.17126/joralres.2020.089

Resumen: Objetivo: Determinar la expresión del marcador de membrana óseo CD44 en muestras de hueso alveolar previamente regenerado con aloinjerto, xenoinjerto y mezcla mediante la técnica de regeneración ósea guiada. **Material y Métodos:** Con aval del Comité de Investigación y Ética, se realizó un estudio exploratorio. Por muestreo intencional y firma de consentimiento informado de donación, se tomaron durante la colocación del implante, 20 muestras de hueso alveolar previamente regenerado con terapia

de regeneración ósea guiada con injerto óseo particulado y membrana. Las muestras fueron teñidas con hematoxilina-eosina para el análisis histológico y por inmunohistoquímica para la detección del CD44. **Resultados:** Los cortes con hematoxilina-eosina mostraron tejido óseo con presencia de matriz osteoide y matriz ósea madura de aspecto usual. De las muestras CD44+, 80% fueron de aloinjerto y 20% de xenoinjerto. Las muestras con aloinjerto-xenoinjerto fueron negativas. No hubo diferencias en la intensidad de la expresión del CD44 entre las muestras positivas. El marcador se expresó en osteocitos, células estromales, infiltrado mononuclear y algunos histiocitos. El 80% de las

muestras CD44+ y el 100% de las muestras con marcación de 60 o más células correspondían a aloinjertos ($p=0,000$). El 67% de las muestras del sector anterior y el 40% del sector posterior fueron CD44+ ($p=0,689$). **Conclusión:** Este estudio muestra por primera vez que la regeneración ósea guiada usando aloinjertos, es más eficiente para la generación de hueso maduro determinado por la expresión de CD44, comparado con el uso de xenoinjertos y mezcla de aloinjerto-xenoinjerto, independientemente del sector anatómico regenerado.

Palabra Clave: Regeneración ósea; receptores de hialuronos; osteocitos; implantes dentales; aloinjertos; xenoinjertos.

INTRODUCTION.

Edentulism is one of the main causes of alveolar bone loss. In Colombia, 5.2% of the population suffer from total edentulism.¹ Measurements in Colombian patients show an average bone of 6 mm in the upper jaw, and 10.9 mm in the lower jaw.² Bone loss makes it difficult to rehabilitate patients with edentulism through implant placement. These patients require additional procedures such as guided bone regeneration (GBR), which relies on the formation of new bone through bone grafts (autologous, homologous, heterologous or alloplastic materials), and membranes (resorbable or non-resorbable).³

Current research assessing the quality of new bone seek to study and measure four main factors through histology and histomorphometry procedures:

- 1) percentage of new bone formation,
- 2) percentage of graft particles,
- 3) presence of connective tissue, and
- 4) percentage of contact of the newly formed bone with the particles of residual material remaining from the graft. Comparative results have shown a higher percentage of new vital bone, less percentage of residual non-vital bone, and more bone formed in tissues grafted with allografts than with xenografts. In both cases, particles of material surrounded by bone, osteoid and osteoblasts, are observed.⁴ These histological findings vary according to the type of material used and the response of each individual.⁵

The alveolar bone is composed of the lamina dura and the cancellous or trabecular bone; within its cellular components are osteoblasts (matrix-generating

cells), osteocytes (mature osteoblasts), osteoclasts (bone macrophages, bone resorption). These cells allow homeostasis in the bone and its constant remodeling.⁶

Osteocytes also participate in the synthesis and mineralization of the osteoid matrix, but their main function is to control bone remodeling. These cells are the final stage of the osteoblastic line, time at which bone maturation is completed, and they are unable to renew themselves.⁷

Bone remodeling involves the participation of osteoblasts and osteoclasts that will generate and reabsorb mineralized connective tissue from the bone. The regulation of this remodeling is complex and requires hormones and local factors that act in an auto- and paracrine way. The molecular events that occur are usually similar to those observed in inflammation and repair processes.⁶

Bone formation and resorption are linked through the RANK ligand/ osteoprotegerin (RANKL/OPG) axis. RANKL, found in osteoblasts, is a transmembrane receptor located on osteoclast precursor cells. The union of RANKL to RANK allows the differentiation of osteoclasts and the initiation of bone resorption. OPG competes with RANK, so when OPG binds to RANKL, the bone resorption process stops. Osteoclast formation involves the fusion of monocyte precursors that occur at the site of bone resorption. The CD44 receptor is necessary for this fusion to take place. The ligand osteoprotegerin is an osteoclast differentiation factor, like RANK.⁸

The main role of CD44 is considered to be the balance between matrix components and osteoprotegerin on

the cell surface.⁹ It acts as a signaling control center for cell surface receptors and provides bone cells with the ability to detect changes in the extracellular environment. CD44 is expressed from mature osteoblasts to osteocytes. Macromolecules such as hyaluronate (HA), osteopontin (OPN), fibronectin and collagen (important regulators of bone remodeling), can bind to CD44 and activate intracellular signals.¹⁰

Therefore, the expression of CD44 in alveolar bone previously grafted for guided bone regeneration may be associated with the presence of osteocytes, activation of macrophages (osteoclasts), and with a correct and active remodeling process,⁷ which would determine the quality of the regenerated bone.

The presence of osteocytes can be evidenced by the expression of the bone marker CD44. This marker is a glycoprotein with cell-cell and cell-matrix adhesion functions expressed in a wide variety of cells and has a large number of known biological functions, within which, is the ability to bind to macromolecules of the matrix, such as fibronectin, collagen and hyaluronate, and its expression in bone cells can be assessed. Osteoclasts and cells of the periosteum also express CD44, although not as strongly as osteocytes. During the early stage of differentiation of the osteocyte, it is embedded in the bone matrix, at this stage it is when the expression of the bone marker CD44 occurs.¹¹

Taking into account that the success of osseointegration in implantology depends among other factors on the quality of the regenerated bone, this research aims to determine the expression of the bone membrane marker CD44 in samples of alveolar bone previously regenerated with allograft, xenograft, and mixed, by means of guided bone regeneration therapy.

MATERIALS AND METHODS.

The present exploratory study was approved by the Research and Ethics Committee of the School of Dentistry of the Pontificia Universidad Javeriana, registration number OD-0160, authorization number 011-2014. Twenty bone samples were taken from a regenerated alveolar bone, both maxillary and mandibular of anterior and posterior areas, of patients previously subjected to a guided bone regeneration therapy with particulate bone graft and resorbable membrane, in alveoli with absence of one or two walls.

Samples from non-smoking patients, without systemic involvement, and without active periodontal

disease were included in the study. Samples showing granulation tissue and regenerative material particles were excluded.

The bone grafts used were cancellous allograft with a particle size ranging from 0.5 mm to 1 mm (Puros®), and resorbable collagen membranes (Biomend®). Regarding the xenograft material, particle size ranged from 0.5 mm to 1 mm (Bioss®). For the allograft-xenograft mix, ratios of 3:1 were used.

At the appointment for implant placement, the patient was asked to donate hard tissue after signing the corresponding informed consent. For each patient from whom the sample was obtained, the following data were recorded: age, sex, type of graft (allograft, xenograft or mixed), and the area in which the regeneration was performed, classified into anterior segment and posterior segment. The sample was taken with a 2 mm diameter trephine bur (Salvin®), at a depth of 5 mm in the previously grafted area.

Immediately after collection, the samples were immersed in 10% formaldehyde buffer solution and transferred to the pathology laboratory of Hospital Universitario San Ignacio, where the tests were performed. After fixation for 24 to 72 hours, the samples were decalcified with 7% ethylenediaminetetraacetic acid, pH 7.0 at 37°C, dehydrated in ethanol gradients, and embedded in paraffin wax at 60°C to form blocks. The latter were subsequently cut to a thickness of 5 µm. Prior to immunohistochemistry, the quality of the sample was evaluated by staining with hematoxylin-eosin, under a light microscope with 10 and 40 X magnification, to evaluate the presence of new and mature bone, and residual bone graft particles.

For staining, the samples were deparaffinized at a temperature of 95°C - 99°C for 20 minutes and washed 3 times with xylol for 3 minutes each. After hydration with alcohol at different concentrations (97%, 80%, 70%), they were stained with hematoxylin for 4 to 6 minutes. The slides were washed and immersed in ammonia water solution to be then stained with eosin for 2 to 4 minutes. Finally, the samples were dehydrated 3 times with alcohol, rinsed 3 times with xylol, and liquid synthetic resin was added to mount the coverslip for reading.

Immunohistochemical analysis for the detection of CD44

For the immunohistochemical test, anti-CD44 (Bio-genex ref: MU310-UC) was used as the primary

antibody. Antigen-antibody reaction was developed with the EnVision FLEX/HRP kit (Dako).

The paraffin embedded samples were cut to a thickness of 3µm. Initially, antigen recovery was carried out for 30 minutes at a constant temperature of 92°C in a Dako PT Link (Dako Colorado INC.) preheated to 65°C. Subsequently, the plates remained immersed in a washing solution (TRIS saline buffer with Tween 20), pH 7.6 (+0.1), and the assembly was carried out on the Dako Autostainer Link 48. For CD44 labeling, staining started with a buffer wash.

Excess liquid was removed, and 100 µl of the peroxidase blocking reagent (EnVision Flex Peroxidase-Blocking Reagent) was added for 5 minutes. It was washed again, and 100 µl of anti-CD44 antibody diluted 1:40 in antibody diluent solution (EnVision FLEX Antibody Diluent) was added and incubated for 20 minutes. After the washing process, 100 µl of EnVision FLEX+ Mouse (LINKER) were added for 15 minutes, it was washed and the reagent containing the enzyme (EnVision FLEX/HRP) was added and incubated for 20 minutes. For the development, two washes with washing solution were carried out, incubating in the buffer during the second wash for 5 minutes.

Finally, 200µl of the substrate (EnVision FLEX Substrate Working Solution) were added for 10 minutes, washed with the wash buffer and then with distilled water. Harris hematoxylin (EnVision TM FLEX Hematoxylin) was used for contrast, the samples were dehydrated with ethanol at increasing concentrations,

covered with resin and coverslips, for reading with a light microscope.

Analysis of data

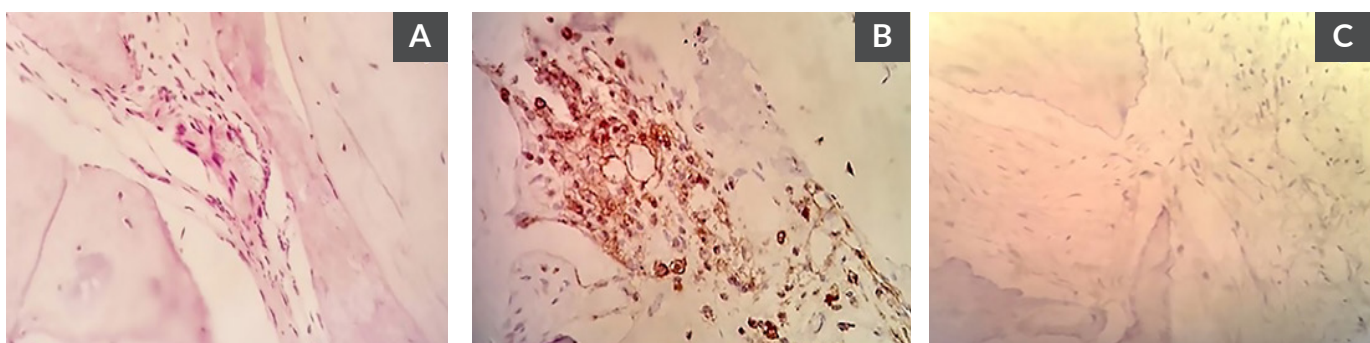
Initially, the intensity of the labeling was determined using a scale from 1 to 4, where 1 was negative, and 4 was the highest intensity. In the samples positive for CD44, the percentage of positive cells per field was established in three categories: less than 30%, between 30-60%, and >60%.

The presence of CD44-positive cells was considered an indicator of mature bone suitable for implant placement. The results are presented in a descriptive way in summary measures for the quantitative variables, and the expression of CD44 for each one of the positive samples. The bivariate analysis was performed using Fisher's exact test ($p<0.05$).

RESULTS.

Of the total of 20 samples collected, one was excluded because it contained particles of the material used for regeneration. The results are then shown for 19 samples from patients with a mean age of 59.4 ± 7.8 years, of which 15 were female and 4 male (Table 1). The mean time for taking the sample was 8.58 months (range 5-16 months) for allograft use, 11.75 months (6-22 months) for xenograft, and 7.67 months (5-10 months) for the allograft-xenograft mix. The most widely used type of graft was allograft with twelve samples, followed by four xenograft-regenerated samples, and the allograft-xenograft mix with three samples.

Figure 1. Representative photomicrographs of the analyses in previously regenerated bone.



A. Sample stained with hematoxylin-eosin (40x). B. Sample positive for the expression of the CD44 marker (40x). C. Negative sample for the expression of the CD44 marker (40x).

Table 1. Characteristics of samples analyzed for CD44.

Age	Sex	Type of graft	Regeneration site	Post-graft healing time (months)	Intensity of staining	%CD44 + cells
72	Male	Allograft	Anterior	6	3	<30
70	Female	Allograft	Anterior	5	4	>60
60	Female	Allograft	Anterior	16	3	<30
62	Female	Allograft	Posterior	6	2	30-60
71	Female	Allograft	Anterior	7	2	<30
53	Female	Allograft	Posterior	6	4	30-60
50	Female	Allograft	Posterior	10	4	30-60
53	Female	Allograft	Anterior	12	3	<30
67	Male	Allograft	Posterior	7	Negative	0
58	Male	Allograft	Posterior	6	Negative	0
64	Female	Allograft	Posterior	12	Negative	0
50	Female	Allograft	Posterior	10	Negative	0
49	Female	Xenograft	Anterior	10	4	<30
65	Female	Xenograft	Posterior	9	2	<30
50	Male	Xenograft	Posterior	6	Negative	0
63	Female	Xenograft	Anterior	22	Negative	0
64	Female	Allograft-xenograft	Anterior	10	Negative	0
51	Female	Allograft-xenograft	Anterior	8	Negative	0
56	Female	Allograft-xenograft	Posterior	5	Negative	0

Nine samples corresponded to regeneration in the anterior segment, and 10 samples in the posterior segment. The initial evaluation of the quality of the samples by means of hematoxylin-eosin staining showed bone tissue sections with the presence of osteoid matrix and mature bone matrix of usual appearance (Figure 1A).

In the immunohistochemical analysis, 10 of the 19 samples were positive for the expression of the CD44 marker. In addition to the expression of the marker in osteocytes, positive stromal cells were found in the mononuclear infiltrate and in some histiocytes (Figure 1B). Figure 1C shows a negative sample for the expression of the marker.

The characteristics of the 10 CD44-positive samples are presented in Table 1. Most of them were obtained from females; 80% of the CD44+ samples, and 100% of the samples with 30 or more cells labelled corresponded to allografts ($p=0.000$). Regarding the intensity of expression, a similar behavior was observed between the two types of grafts. No differences were

found in the comparison of regenerated areas, nor a relationship between healing time and the presence or absence of the marker. None of the samples taken from areas regenerated with allograft-xenograft showed expression of CD44.

DISCUSSION.

One of the current therapies to treat edentulism is the placement of dental implants, although one of its main problems is insufficient bone volume. When an extraction is performed, the lamina dura or fascicular bone, measuring approximately 400µm, is lost. Taking into account that about 80% of the population has a vestibular table of less than 1mm, an extraction leads to loss of the table and bone resorption in both height and thickness.^{12,13}

This is why it is required to increase bone volume using guided bone regeneration for the functionality of the dental implant placement. One of the objectives of this procedure is for the newly formed alveolar bone, where the placement of a dental implant is planned,

to share physical and histological characteristics with the mature native bone. This maturation phase may be evidenced by the presence of osteocytes, since this cell represents the final stage of the osteoblastic line⁷ through the use of a marker such as CD44,¹¹ which is the aim of this study.

The results showed a higher frequency and intensity of CD44 positive cells in tissues taken from regenerated sites with allografts, compared with xenografts, or the combination of the two. Allografts contain bone morphogenetic proteins (BMP) in low proportions, which gives them osteoinductive and osteoconductive properties, making them a suitable material for oral regenerative treatments.¹⁴ Thirteen different morphogenetic proteins (BMP1-BMP13) have been identified that act as osteoinductive components and promote bone neof ormation.¹⁵

However, some allograft samples and most xenografts were negative for CD44 expression. Allografts have a faster resorption rate of 3 to 6 months,¹⁶⁻¹⁸ which leads to a reduction in the time to start bone activity, compared to xenografts that have a slower resorption rate of 4 to 12 months.³ These wide ranges can make a difference in the goal of ensuring that the regeneration procedure leads to the production of mature bone for implant placement. In addition to the difficulty of standardizing the different time ranges that depend on the type of material used, in this study, not all patients were available to take the sample at the indicated time, which meant that the average time was higher than that indicated by consensus. Although this is one of the limitations of the study, no relationship was found between the graft healing time and the presence or absence of the CD44 marker.

If we consider that the positive expression of CD44 can be taken as a marker of bone maturation, it is relevant to redefine healing times based on the expression of this marker. None of the allograft and xenograft mixtures was positive for CD44. If for these cases the healing time is taken from the allograft, some xenograft particles may remain and slow down the maturation of the new bone by requiring longer resorption times, and even persisting for more than 10 years in the regenerated area.¹⁹

It is important to take into account the half-life and the apoptosis process of osteocytes since these two factors can influence the non-expression of the CD44 marker in regenerated tissue samples. The osteocyte is a metabolically underactive mature cell that has a half-life of 150 days, after which it regresses and dies

(20). Osteocytes reside both in the mineralized bone matrix and in small gaps, and that is why they are not considered migratory cells, which facilitates their identification. Sixty-five percent of osteocytes die by apoptosis during the process of repair of the cavity eroded by osteoclasts.²⁰

Recently, CD44-positive bone marrow-derived cells have been shown to be essential for the repair of bone defects in an animal model using tissue-engineered constructs.²¹ This confirms the use of the CD44 marker as a way to assess bone quality in tissue regeneration models. It must also be considered that graft materials act as a scaffold for the new bone formation, but this does not imply that the migration of cells takes place, which is why not all osteoblasts will end up converted into osteocytes.²¹

There are few articles that study the expression of CD44. Most of the studies were carried out in animals, and only one studied the expression of CD44 in regenerated bone in humans, in which xenograft samples used in sinus lift regenerations are analyzed. The samples were taken 6 months after the sinus floor elevation was performed, with a positive labeling of 74%.²² However, it is not possible to make a comparison with the present results since it does not meet the criteria for classical regeneration of the alveolar ridge, as it is being done at the expense of a defect described as ideal for vertical regeneration such as Highmore's antrum, or maxillary sinus.

For clinicians it is important to have some type of parameter to establish the degree of bone maturation, which ensures a predictable bone resorption/apposition dynamics such as that seen in non-regenerated native bones, which allows to achieve adequate stability of the implant in the bone, support the subsequent loading of that implant, and resist the occlusal forces to which the implant is subjected when in function.

Few published studies show the impact of the type of graft on the performance of implants. In the systematic review published by Chavda *et al.*,²³ they draw a general conclusion that there are no differences in the success of implants between the types of materials for alveolar ridge augmentation. However, the analysis of the available literature shows very few articles that look for these relationships, and the few that exist present controversial results, diversity of procedures, patients (age and smoking habit, for example), and types of grafts used.

These authors suggest conducting comparative studies especially between grafts from non-autogenous

sources such as allo- and xenografts. Therefore, more studies are required to establish the most efficient type of graft in restoring lost alveolar bone, with a behavior similar to that of native or healed alveolar bone without any type of regeneration, both from the biological point of view, and in the clinical relevance of associating the type of graft with implant failure.

The selection of the bone graft has been defined by commercial rather than biological criteria, possibly more by the quantitative availability than by the search for the reconstruction of the alveolar process in a more natural way.

Traditionally, different mixtures of bone grafts of the autologous type (from the same patient), homologous (from a human bone bank) and heterologous (from other species such as pigs or bovines) have been used, with the only parameter of observing bone in the biopsies through histological tests, without confirming if it is a suitable, mature bone that allows the placement of dental implants, and subsequently, determine its capacity to bear load and stay healthy for long periods of time. The authors of this study consider that the approach used in this research is a good starting point to begin to establish clearer protocols, by providing a valuable biological explanation of the best way to regenerate alveolar bone.

CONCLUSION.

Guided bone regeneration using allografts is more efficient for the generation of mature bone determined by the expression of CD44, compared to the use of xenografts and allograft-xenograft mix, regardless of the regenerated anatomical sector. These results may be a starting point for the study of the ideal maturation times of this previously grafted bone.

Conflict of interests: All the authors declare no conflict of interest in the execution of this project.

Ethics approval: Research and Ethics Committee of the Faculty of Dentistry of the Pontificia Universidad Javeriana. Code: OD-0160. Authorization number: 011-2014.

Funding: This research was funded by the Faculty of Dentistry, Pontificia Universidad Javeriana, ID PPTA 6643, ID PRY 6769.

Authors' contributions: RED-V, AR-C: Conceptualization, methodology, information analysis, editing and revision of the manuscript, supervision, project management. LBB-G, DSH-C: Conceptualization, methodology, information analysis, writing and preparation of the draft of the manuscript. MO-C: methodology, information analysis, writing and preparation of the draft of the manuscript. NSR-M: methodology, project management, obtaining funds.

Acknowledgements: To Derna Luz Castro Pontón for her valuable contribution in the standardization, execution and reading of immunohistochemical tests.

REFERENCES.

1. Estudio Nacional de Salud Bucal - ENSAB IV. Ministerio de Salud y Protección Social, República de Colombia. 2014.
2. Escolano Rivas J, Barrientos Sánchez S, Rodríguez Ciodaro A. Frecuencia y características de hallazgos y variaciones óseas en radiografías panorámicas de personas con edentulismo total. *Univ Odontol.* 2018; 36(78).
3. Jung RE, Ioannidis A, Hämmerle CHF, Thoma DS. Alveolar ridge preservation in the esthetic zone. *Periodontol* 2000. 2018;77(1):165-75.
4. Froum SJ, Wallace SS, Elian N, Cho SC, Tarnow DP. Comparison of mineralized cancellous bone allograft (Puros) and anorganic bovine bone matrix (Bio-Oss) for sinus augmentation: histomorphometry at 26 to 32 weeks after grafting. *Int J Periodontics Restorative Dent.* 2006;26(6):543-51.
5. Solakoglu Ö, Götz W, Heydecke G, Schwarzenbach H. Histological and immunohistochemical comparison of two different allogeneic bone grafting materials for alveolar ridge reconstruction: A prospective randomized trial in humans. *Clin Implant Dent Relat Res.* 2019;21(5):1002-16.
6. Sodek J, Mckee MD. Molecular and cellular biology of alveolar bone. *Periodontol.* 2000; 24(2): 99-126.
7. Boyce BF. Advances in the regulation of osteoclasts and osteoclast functions. *J Dent Res.* 2013;92(10):860-7.
8. Cao JJ, Singleton PA, Majumdar S, Boudignon B, Burghardt A, Kurimoto P, Wronski TJ, Bourguignon LY, Halloran BP. Hyaluronan increases RANKL expression in bone marrow stromal cells through CD44. *J Bone Miner Res.* 2005; 20(1):30-40.
9. Wang X, Du Z, Liu X, Song Y, Zhang G, Wang Z, , Gao Z5, Wang Y, Wang W. Expression of CD44 standard form and variant isoforms in human bone marrow stromal cells. *Saudi Pharm J.* 2017;25(4):488-491.
10. Li Y, Zhong G, Sun W, Zhao C, Zhang P, Song J, Zhao D, Jin X, Li Q, Ling S, Li Y. CD44 deficiency inhibits unloading-induced cortical bone loss through downregulation of osteoclast activity. *Sci Rep.* 2015;5:16124.
11. Hughes DE, Salter DM, Simpson R. CD44 expression in human bone: a novel marker of osteocytic differentiation. *J Bone Miner Res.* 1994; 9(1): 39-44
12. Prakash MS, Ganapathy DM, Nesappan T. Assessment of labial alveolar bone thickness in maxillary central incisor and canine in Indian population using cone-beam computed tomography. *Drug Invention Today* 2019; 11(3), 712-14.
13. Dos Santos JG, Oliveira Reis Durão AP, de Campos Felino AC, Casaleiro Lobo de Faria de Almeida RM. Analysis of the buccal bone plate, root inclination and alveolar bone dimensions in the jawbone. A descriptive study using cone-beam computed tomography. *J Oral Maxillofac Res.* 2019; 10(2).
14. Schwarz F, Ferrari D, Sager M, Herten M, Hartig B, Becker J. Guided bone regeneration using rhGDF-5- and rhBMP-2-coated natural bone mineral in rat calvarial defects. *Clin Oral Implants Res.* 2009;20(11):1219-30.
15. Yao W, Shah B, Chan H-L, Wang H-L, Lin G-H. Bone Quality and Quantity Alterations After Socket Augmentation with rhPDGF-BB or BMPs: A Systematic Review. *Int J Oral Maxillofac Implants.* 2018;33(6):1255-65.
16. Bartee BK. Extraction site reconstruction for alveolar ridge preservation. Part 1: rationale and materials selection. *J Oral Implantol.* 2001; 27 (4): 187-93.
17. Papečkys V, Rusilas H, Pranskunas M. Comparison of Bone grafts for Alveolar ridge dimensional preservation. *JIMD.* 2018; 5(1): 20-9.
18. Sartori S, Silvestri M, Forni F, Icaro Cornaglia A, Tesesi P, Cattaneo V. Ten year follow-up in a maxillary sinus augmentation using anorganic bovine bone (Bio-Oss). A case report with histomorphometric evaluation. *Clin Oral Implants Res.* 2003; 14 (3): 369-72.
19. Vargas Rico L, Serrano Méndez CA, Estrada Montoya J H. Preservación de alvéolos postexodoncia mediante el uso de diferentes materiales de injerto. *Revisión de la literatura. Universitas Odontológica.* 2012; 31(66): 145-83
20. Schaffler MB, Kennedy OD. Osteocyte signaling in bone. *Curr Osteoporos Rep.* 2012; 10(2): 118-25.
21. Lu Y, Xing J, Yin X, Zhu X, Yang A, Luo J, Gou J, Dong S, Xu J, Hou T. Bone Marrow-Derived CD44+ Cells Migrate to Tissue-Engineered Constructs via SDF-1/CXCR4-JNK Pathway and Aid Bone Repair. *Stem Cells Int.* 2019;2019:1513526.
22. Galindo-Moreno P, Hernández-Cortés P, Aneiros-Fernández J, Camara M, Mesa F, Wallace S, O'Valle F. Morphological evidences of Bio-Oss® colonization by CD44-positive cells. *Clin Oral Implants Res.* 2014; 25 (3): 366-71.
23. Chavda S, Levin L. Human studies of vertical and horizontal alveolar ridge augmentation comparing different types of bone graft materials: A systematic review. *J Oral Implantol.* 2018;44(1):74-84.