

## Orthognathic Surgery with anterior segmental osteotomy as alternative of treatment in patients with dento-skeletal deformity Class III AP maxillary deficiency with dental compensation. Case report.

Cirugía Ortognática Con Osteotomía Segmentaria Anterior Como Alternativa De Tratamiento En Pacientes con deformidades dento esqueléticas (DDE) Clases III Por Deficiencia AP Maxilar Compensados Dentalmente: Caso Clínico.

Carlos Millán-Golindano.<sup>1</sup>

Josmar García.<sup>1</sup>

Julio Tebres.<sup>1</sup>

Hans Cordsen.<sup>2</sup>

### Affiliations:

<sup>1</sup>Hospital General Del Oeste "Dr. José Gregorio Hernández" Caracas, Venezuela.

<sup>2</sup>Buco-maxilofacial and Traumatology Surgery department. Hospital General Del Oeste "Dr. José Gregorio Hernández", Caracas, Venezuela.

**Corresponding author:** Julio Tebres. Hospital General Del Oeste "Dr. José Gregorio Hernández" Caracas, Venezuela. E-mail: [odjctebres@gmail.com](mailto:odjctebres@gmail.com)

Receipt : xx/xx/2020 Revised: xx/xx/2020  
Acceptance: xx/xx/2020

### Cite as:

Millán-Golindano C, García J & Cordsen H. Orthognathic Surgery with anterior segmental osteotomy as alternative of treatment in patients with dento-skeletal deformity Class III AP maxillary deficiency with dental compensation. Case report. J Oral Res 2020; 9(5):423-429.  
Doi:[10.17126/joralres.2020.084](https://doi.org/10.17126/joralres.2020.084)

**Abstract: Introduction:** Orthognathic surgery is a routine procedure carried out by maxillofacial surgeons in patients with dento-skeletal deformations (DSD) with the objective of achieving functional and esthetical satisfactory results. However, some in cases, due to the decision of the patient or the orthodontic team, the occlusion is tried to be compensated with the intention of avoiding surgery, without optimal results. As a consequence, some extra procedures are required in the surgery to correct and obtain better results.

**Objective:** The aim of this case is to propose the anterior segmental osteotomy (ASO) as alternative of treatment in patients with dento-skeletal deformity class III with maxillary and para-nasal deficiency which have been orthodontically compensated. **Material and methods:** A 18 years old female with DED Class III due anterior-posterior (AP) maxillary and paranasal deficiency and AP mandibular excess. The surgery was carried out through Le Fort I osteotomy in combination with a segmentary osteotomy at the expense of first premolars and bilateral setback sagittal split osteotomy (BSSO). Clinical and imageology post operatory controls were made during the first 6 months and at two years. **Results:** Through the realization of the anterior segmental osteotomy the correction of occlusal and transversal alterations of the patient maxilla were performed and additionally favorable facial changes were obtained. **Conclusion:** The initial orthodontic management of patients with DSD will influence the surgical procedures and the achievement of a balance between esthetics and function. This illustrates why the treatment of these patients must be multidisciplinary; the treatment that was chosen in this case was innovative and could be an alternative for the treatments of patients with DED Class III.

**Keywords:** Orthognathic surgery; Orthognathic Surgical Procedures; Dento-facial Deformities; Malocclusion, Angle Class III; Orthodontics, Corrective; Maxilla.

**Resumen: Introducción:** La cirugía ortognática es un procedimiento de rutina que realizan los cirujanos bucomaxilofaciales en pacientes con deformidades dento esqueléticas (DDE) con la finalidad de lograr un resultado funcional y estético satisfactorio. Sin embargo, hay casos en los cuales, ya sea por decisión del paciente o por el ortodoncista, se intenta compensar la oclusión con el fin de evitar la fase quirúrgica no obteniendo los resultados más óptimos; y como consecuencia, se requiere de procedimientos adicionales a los convencionales en la cirugía para corregir y lograr el mejor resultado. **Objetivo:** El propósito de este caso es proponer la osteotomía segmentaria anterior (OSA) como alternativa de tratamiento en pacientes con Deformidad Dento Esquelética clase III con deficiencia maxilar y paranasal los cuales han sido compensados ortodonticamente. **Material y Métodos:** Paciente femenina de 18 años de edad con Deformidad Dento Esquelética Clase III por deficiencia AP maxilar y paranasal y exceso AP mandibular. Se realiza cirugía mediante osteotomía Le Fort I

en combinación con osteotomía segmentaria a expensas de primeros premolares, osteotomía sagital de rama bilateral de retroposición. Se realizan controles post-operatorios clínico e imagenológicos durante los primeros 6 meses. Resultados: Por medio de la realización de la osteotomía segmentaria anterior se pudo realizar la corrección de las alteraciones oclusales y transversales del maxilar de la paciente, además de producir cambios faciales favorables. **Conclusión:** El manejo inicial de los pacientes con deformidades dento-esqueléticas por parte del ortodoncista va influir en los procedimientos quirúrgicos y en lograr un balance entre lo estético y lo funcional, por lo que el tratamiento en estos pacientes es multidisciplinario; el tratamiento realizado en este caso en una solución innovadora y puede llegar a tomarse como alternativa en los tratamientos de las clases III.

**Palabra Clave:** Cirugía Ortognática; Procedimientos Quirúrgicos Ortognáticos; Deformidades Dentofaciales; Maloclusión de Angle Clase III; Ortodoncia Correctiva; Maxilar.

## INTRODUCTION.

Facial aesthetics plays an important role in the acceptance and social development of the individual. It covers not only the smile, but also the profile and harmony of its components. There are patients with dento-skeletal deformities (DSD), whose treatment is not only orthodontic but also requires orthognathic surgery, This is an important point to be considered by the orthodontist, since the consultation presents patients whose resolution must be guided in order to achieve a balance between aesthetics and functionality, moreso during adolescence when they can take advantage of the growth potential to correct these deformities that affect both facial growth and dentition development.<sup>1,2</sup>

The class III malocclusions are considered one of the harder orthodontic problems to treat, either the occlusal and functional interferences or, skeletal discrepancies between maxilla and mandible (maxillary retrusion, mandibular prognathism or a combination of both).<sup>3,4</sup>

The orthodontic camouflage is a viable treatment alternative (when the discrepancy between maxilla and mandible is mild or moderate), fixing the malocclusion through the pro inclination of the upper incisors and retro inclination of lower incisors through distalization

or extractions in the lower arch.<sup>4</sup>

However, if the discrepancy between maxilla and mandible is severe, especially in adult patients, it is complicated to achieve a dental movement via orthodontics only .

To achieve a good diagnostic and set an adequate treatment plan a clinical, imaging (x-rays, topographies, intra and extra oral photographs), study and work models on semi-adjustable articulator mounts simulating the malocclusion to be corrected must be done (considering the limits of the case).<sup>5-7</sup>

Patients with class III DDE, who present canine and molar Angle class I occlusion and ideal overjet, represent a challenge to perform maxillary advancement and mandibular retrusion movements, since by not having a negative overjet, correction of the deformity is prevented. This limits the surgical alternatives, and as such, in conjunction with the orthodontist the treatment plan may include an anterior segmental osteotomy with the objective to setback the anterior dental segment as the first step and generate a negative overjet, then in the same surgical intervention advance en bloc the LeFort I osteotomy of the maxilla, obtaining a stable canine class I/molar class II occlusion and an adequate facial profile.<sup>7-10</sup>

## CASE REPORT

### Clinical Case

18 years old female patient, ASA I, presented to consultation in the Department of Maxillofacial Surgery of West General Hospital "Dr. José Gregorio Hernández" referring that she had received orthodontic treatment, where compensation was made in his dentition, through changes in the position of the teeth, but who currently presented facial aesthetic disagreement.

### Clinical characteristics

Facial asymmetry due left hemi-face, diminished mid facial third, increased lower facial third, hypertonicity of the mental muscles, mild deviation of middle line on the chin to the right, concave profile, infra-orbital and paranasal deficiency, nasal infratip, closed nose-lip angle, mild antero-posterior excess of the mandible and chin.

### Occlusal Characteristics

Canine and molar Angle Class I, edge to edge bite (Figure 1A, Figure 1B and Figure 1C). Presurgical imaging was obtained, including lateral skull cephalic, panoramic and postero-anterior cephalic with Legan/Burstone and predictive Epker cephalometric analysis (Table 1 and Figure 1D).

### Treatment plan

After the study of the case the decision was made to perform a modified anterior segmental osteotomy at the expenses of teeth 1.4 and 2.4, quadrangular Le fort I osteotomy of 4mm of advancement and 4mm posterior

impaction, setback bilateral sagittal split osteotomy until the occlusion engage. Informed consent from the patient was obtained.

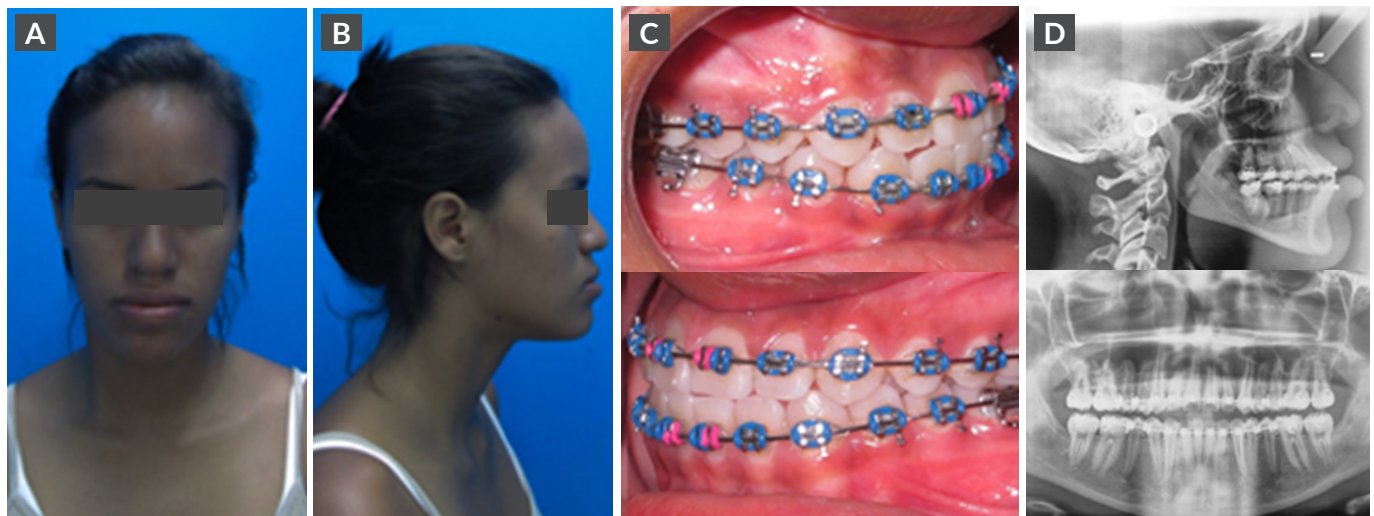
The surgery began with the marking of the quadrangular Le fort I osteotomy, marking of the segmentary osteotomy at the expense of first premolars in a convergent way to the apex, with extension of one cut line that intercepts the marking at the level of the quadrangular Le Fort, allowing to maintain the maxillary length and the location of the piriform segment to greater paranasal projection, (Figure 2A).

Once the marking of the osteotomies was completed, the pterigo-maxilla disjunction was initiated, and then completed with disjunction of the nasal septum and nasal walls to finally make the downwards fracture and in this way complete the osteotomy in the nasal floor (Figure 2A).

When all osteotomies are finished, the retro position of the anterior segment of the maxilla is made with a palatal plate, then an intermediate splint is needed to place the maxilla in the planned position. To establish the maxilla a rigid fixation is needed achieved by placing L plates of 2.0 system of 4 holes on nasal-maxillary buttresses and then a lined plate of 3 holes in a zygomatic buttress. (Figure 2C)

The movement executed in a sagittal way downwards, plus the impaction of 4mm in the posterior segment of the maxilla, projected the naso-genian zone and improved the upper-anterior dental position (Image 4C).

Figure 1. Occlusal Characteristics



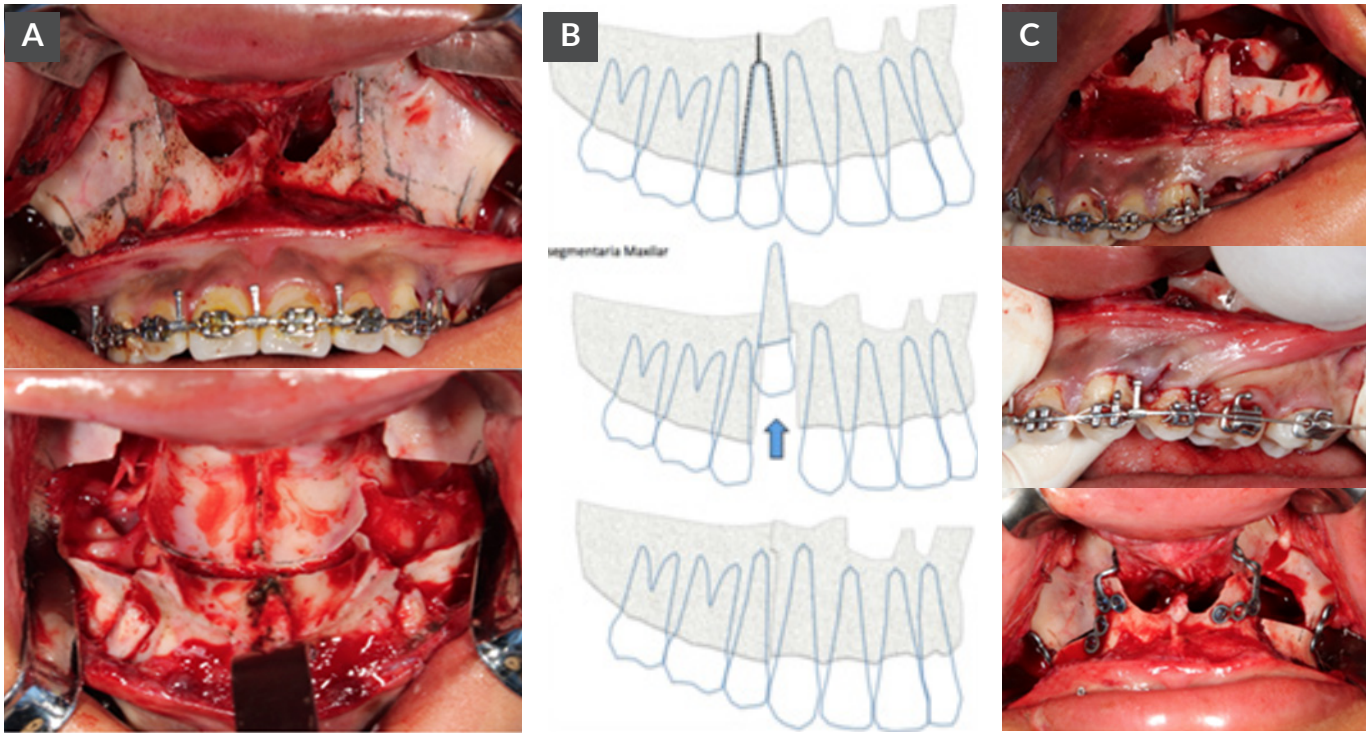
A. Frontal photograph. B. Profile Photograph I. C. Intra-oral photographs. D. Lateral Cephalic Rx and panoramic.



A bilateral sagittal split osteotomy was performed in the mandible until occlusion was achieved, and it was fixed with a 5-hole 2.0 system plate (Osteomed®). Clinical and imaging post-surgical follow ups were performed

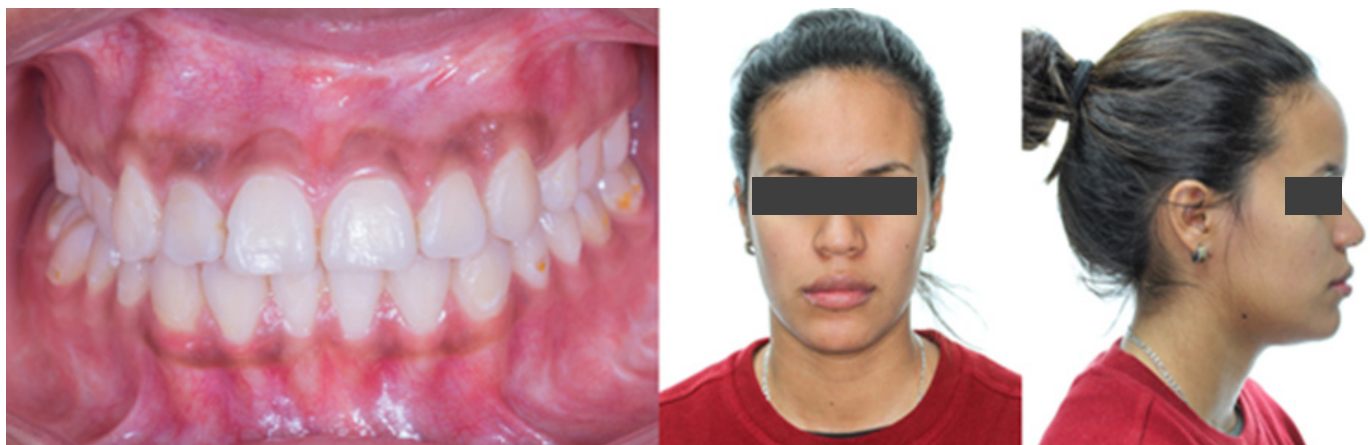for 2 years, and an improvement of the facial profile was evidenced, ideal overjet, canine class I and molar class II. Two years post-surgical images (Image 5).

**Figure 2.** Treatment plan.



A. Shows marks for Le fort I and segmentary osteotomy at expenses of dental organs 1.4 and 2.4 (first premolars). B. Illustrative image of anterior segmental osteotomy. C. Rigid fixation with osteosynthesis material (Osteomed®). Space closed due the segmentary plus extraction of dental organs 1.4 and 2.4.

**Figure 3.** Post-surgical follow up at two years.



**Table 1.** Interpretation of cephalometric analysis.

Measure	Skeletal Measures in horizontal plane / Vertical Plane		
	Patient	Norm	Clinic correlation
Nasion/A Point/Pogonion	-9°	3° +- 5°	Shows Growing pattern class III
Nasion/Orbit	-23mm	14mm +- 3mm	Infra-orbit deficiency
Nasion/ A point	- 8 mm	- 1mm +- 3mm	Antero-posterior maxilla deficiency
Nasion/B point	1mm	-6mm +- 2mm	Antero-posterior excess
Nasion/Pogonion	2mm	-5 mm +- 4mm	Mental antero-posterior excess
Nasion- Ant. Nasal Spine/ Ant. Nasal Spine/ -Mental (N-ENA/ENA-Me)	0.7	8.0	Vertical increase of inferior third with respect of middle third
1inf/Mandibular Plane	47mm	43mm +-2mm	Increase of inferior sub- unit

## RESULTS

Through the performance of the anterior segmental osteotomy, it was possible to correct the occlusal and transverse alterations of the patient's maxilla, in addition to producing favorable facial changes.

## DISCUSSION.

Initial orthodontic treatment is a determining factor in patients who need or require or require surgical treatment, since it conditions the behavior to be followed by the surgeon, which is why a thorough evaluation of the patient is important to guide him and carry out the ideal treatment , thus avoiding compensations that later complicate orthognathic surgery.

The Lefort I osteotomy with anterior segmental is a useful complement in the management of transverse and vertical discrepancies of the maxilla. The main indications are single-stage corrections of the maxillary transverse deficiency, correction of the anterior open bite where there is an appreciable difference in the occlusal plane not susceptible to orthodontic correction, and vertical correction of the anterior portion of the maxilla.<sup>5,8</sup>

Segmental osteotomy is unusual in the correction of occlusal alterations as there are other non-surgical procedures such as orthodontic treatment. Although there are indications for the performance of segmental osteotomies, their limited use is probably due to the lack of training of maxillofacial surgery professionals,

and as such the procedure represents a challenge.<sup>11,12</sup>

It is unusual to use a maxillary segmental osteotomy in patients with DDE Class III, in a study by Taborda.<sup>9</sup> they performed this surgical procedure in four patients, who presented posterior open bite, transverse decrease of the maxilla, posterior crossbite, dentoalveolar prognathism and it was obtained immediate correction of its occlusive alteration. The segmental osteotomy described in all cases was performed in a conventional manner, with two cuts parallel to the root of the dental organ to be extracted, which results in the creation of spaces between the bone segments in the cephalic portion once the planned moment is executed. of the osteotomy; which could be avoided with the proposed osteotomy design in this case.

Ho et al. reports in a study of 85 patients that only 9 presented intra-surgical complications like sinuses communications and bleeding. Eighteen patients presented post surgical complications, four with oral-nasal fistulas, three patients with loss of pulpar vitality, two patients with pseudo-arthrosis, three patients with gingival retraction and eight patients rejected the osteosynthesis material presented repeated infection.<sup>8,13</sup> Short- to medium-term stability is excellent, as many skeletal-origin open bites correct their cephalometric position one year after maxillary surgery, stability in transverse enlargement has been examined in a follow-up study using both clinical and clinical evaluation. study models. Although a small degree of recurrence occurs in the transverse direction, it is

believed to be within acceptable limits of orthodontic stability.<sup>8,9,12,13</sup>

Segmental osteotomies for the management of occlusive alterations are not used frequently, therefore, in the reviewed literature, very few publications were found in this regard. Which leads to a gap in the knowledge of the technique *per se*, as well as its results and probable complications. From the foregoing, the need arises for the groups dedicated to maxillofacial surgery to publish their results with this technique.<sup>8</sup>

## CONCLUSION.

The patients with class III DSD and associated psychosocial problems lead us to take a combined treatment as an alternative: orthodontics complemented with orthognathic surgery, which offers a good option to correct this type of alterations. Both the orthodontist and the surgeon must have experience and must work together in all stages of treatment, both pre and post-surgical.

This article describes the authors' approach to correct dentofacial skeletal deformities that require multi-segmentation of the maxilla. Achieving optimal results requires close collaboration within the orthodontic-surgery team. The importance of paying attention to detail in the course of the surgical procedure cannot be overstated, as complications of avascular necrosis cannot be easily corrected. The multisegmental maxilla is a valuable technique and adds to the versatility of the LeFort I in treating open bites and transverse discrepancies in dentoalveolar deformities.

**Conflict of interests:** The authors declare no conflict of interest.

**Ethics approval:** Informed consent from the patient was obtained.

**Funding:** Self funded. The present paper didn't receive any financial aid from public, commercial agencies or nonprofit organizations.

**Authors' contributions:** All authors contributed to this case report.

**Acknowledgements:** None.

## REFERENCES.

1. Yunuen A, Guzmán I. Tratamiento ortodóncico quirúrgico de una maloclusión CII esquelética severa. Reporte de caso clínico. *Rev Odont Mex.* 2009; 13 (3): 158-164.
2. Wolford L, Karras S, Mehra P. Considerations for orthognathic surgery during growth, Part1: Mandibular deformities. *Am J Orthod Dentofacial Orthop.* 2001; 119 (2): 95-101.
3. Da Silva, L. Consideraciones Generales en el Diagnóstico y tratamiento de las Maloclusiones Clase III. *Rev Latinoam Ortod Odontop.* 2005.
4. Mariuxi L, López D. Objetivos que se pueden lograr con un Camuflaje Ortodóncico en pacientes Clase III quirúrgicos. Revisión de la literatura. *Rev Latinoam Ortod Odontop.* 2017; 691-9.
5. Shawky M, El-Ghareeb T, Hameed L. Evaluation of the three-dimensional soft tissue changes after anterior segmental maxillary osteotomy. *International journal of oral and maxillofacial surgery.* 2012; 41(6): 718-26.
6. Ramírez H, Pavic M, Vásquez M. Cirugía ortognática: diagnóstico, protocolo, tratamiento y complicaciones. Análisis de experiencia clínica. *Rev. Otorrinolaringol. Cir Cabeza Cuello.* 2006; 66(3): 221-31.
7. Birbe J, Serra M. Ortodoncia en cirugía ortognática. *RCOE.* 2006; 11 (5): 547-557.
8. Ho M, Boyle M, Cooper JC, Dodd M, Richardson D. Surgical complications of segmental Le Fort I osteotomy. *British J Oral Max Surg.* 2011; 49 (7): 562-6.
9. Tabora M. Osteomías segmentarias del maxilar superior: Experiencia quirúrgica en el Hospital de San José de Bogotá. *R Rep Med Cir.* 2000; 9(2): 17-20.
10. Reyneke J. *Essentials of orthognathic surgery.* Chicago: Quintessence, 2003.
11. Cillo J, Stella J. The push osteotome: An alternative technique to preserve periodontal health in segmental Le Fort osteotomies: Technique and retrospective review. *J Oral Max Surg.* 2005; 63(2): 275-278.
12. Vidal M. Revisión sistemática de la literatura de los cambios tridimensionales de la cirugía segmentada del maxilar superior. [Trabajo Fin de Grado]. Universidad de Sevilla. 2017.
13. Kahnberg K, Hagberg C. The approach to dentofacial skeletal deformities using a multisegmentation technique. *Clin Plastic Surg.* 2007; 34 (3): 477-84.